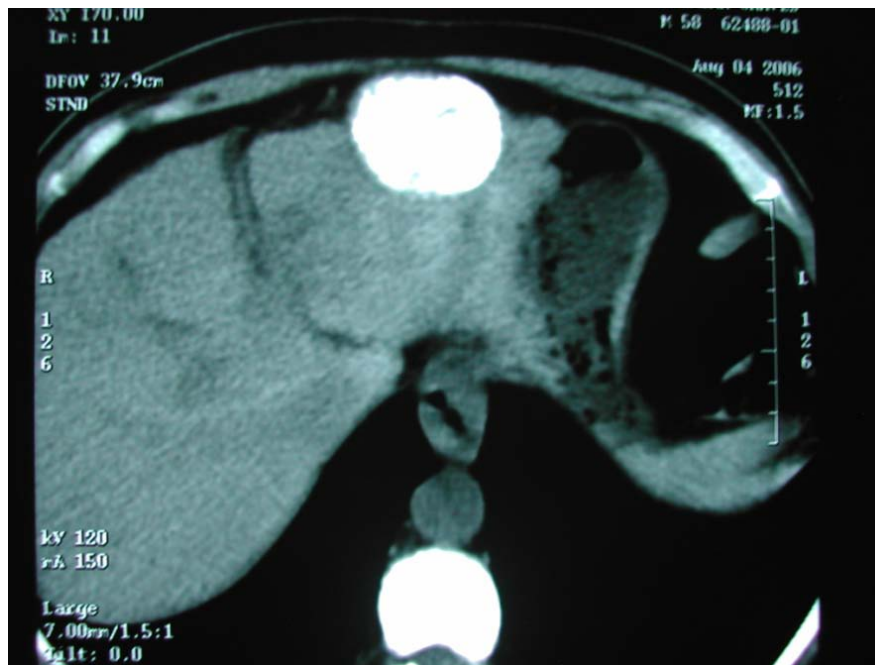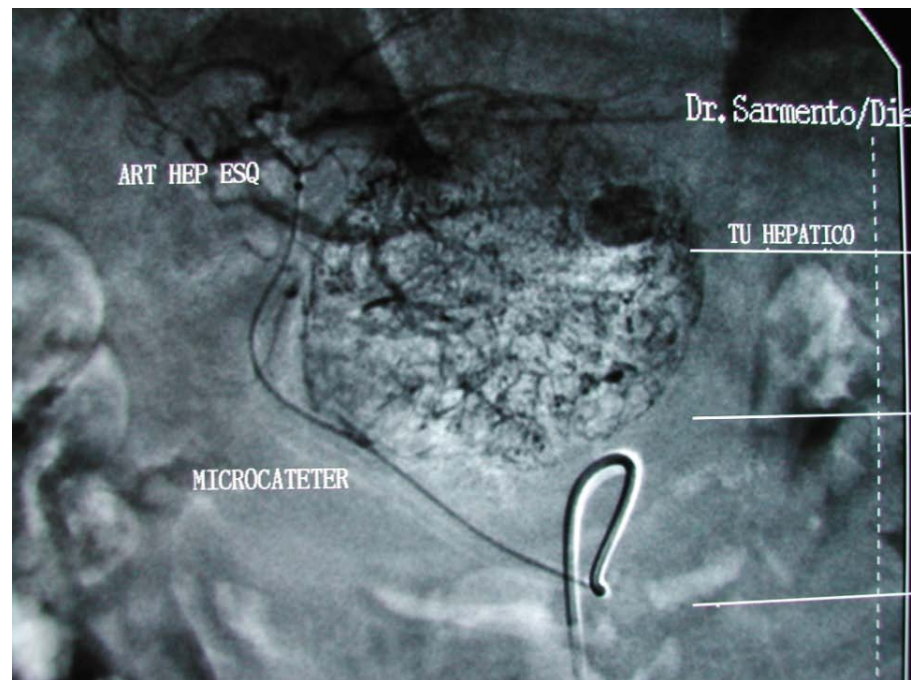
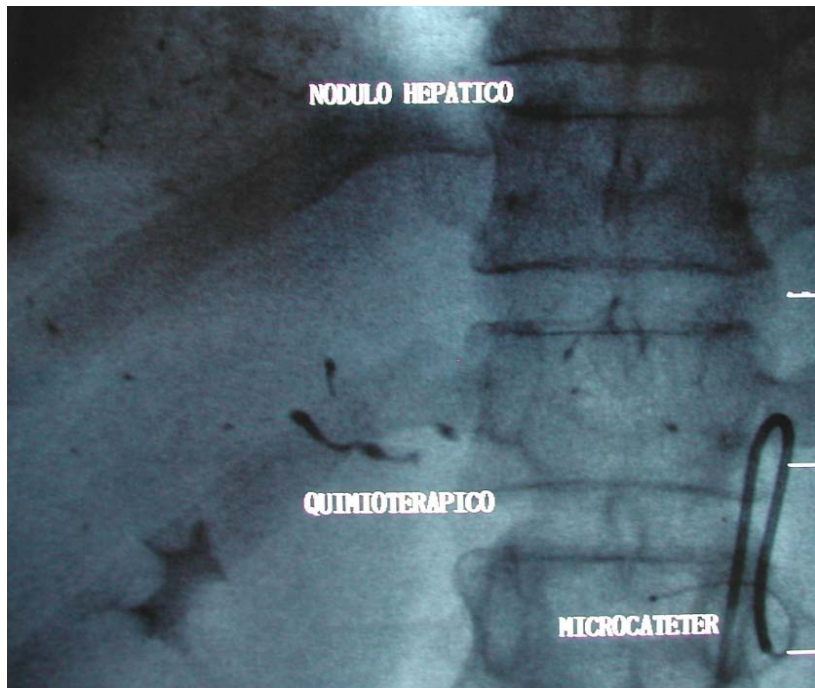
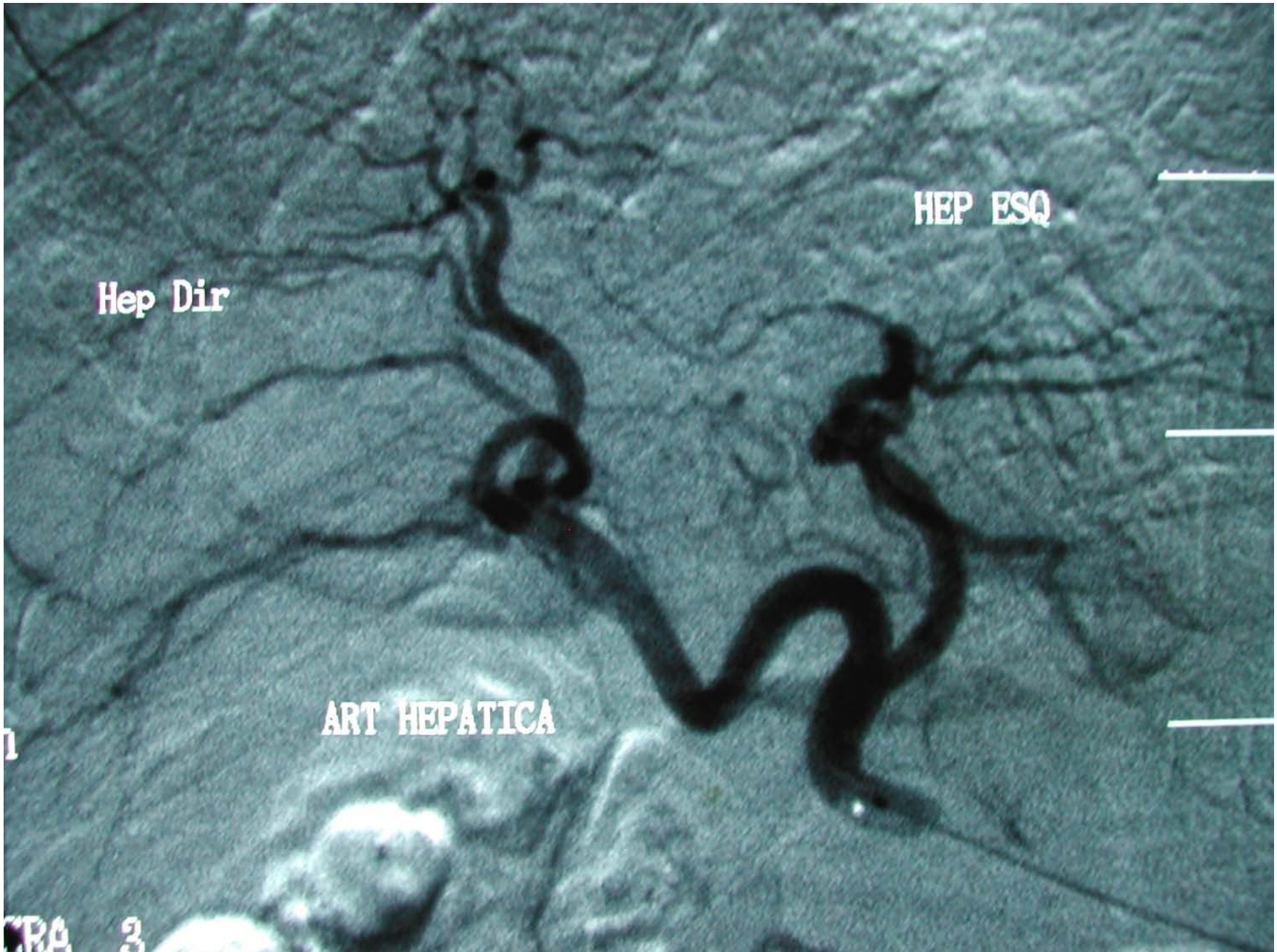


PROCEDIMENTOS
EM
CIRURGIA HEPATO-BILIO-PANCREÁTICA

QUIMIOEMBOLIZAÇÃO



ARTERIOGRAFIA PRÉ-OPERATÓRIA



Hep Dir

HEP ESQ

ART HEPATICA

ULTRASSONOGRAFIA PER-OPERATÓRIA

HUGG

C5-2/60-ABD-[ABDOMEN.]

01/30/2009

10:29:59AM

General

Freq 3.3MHz

Depth 11cm

Sector 100%

Gain 46%

FR High

FPS 30 Hz

Dyn 72dB

Persist 3

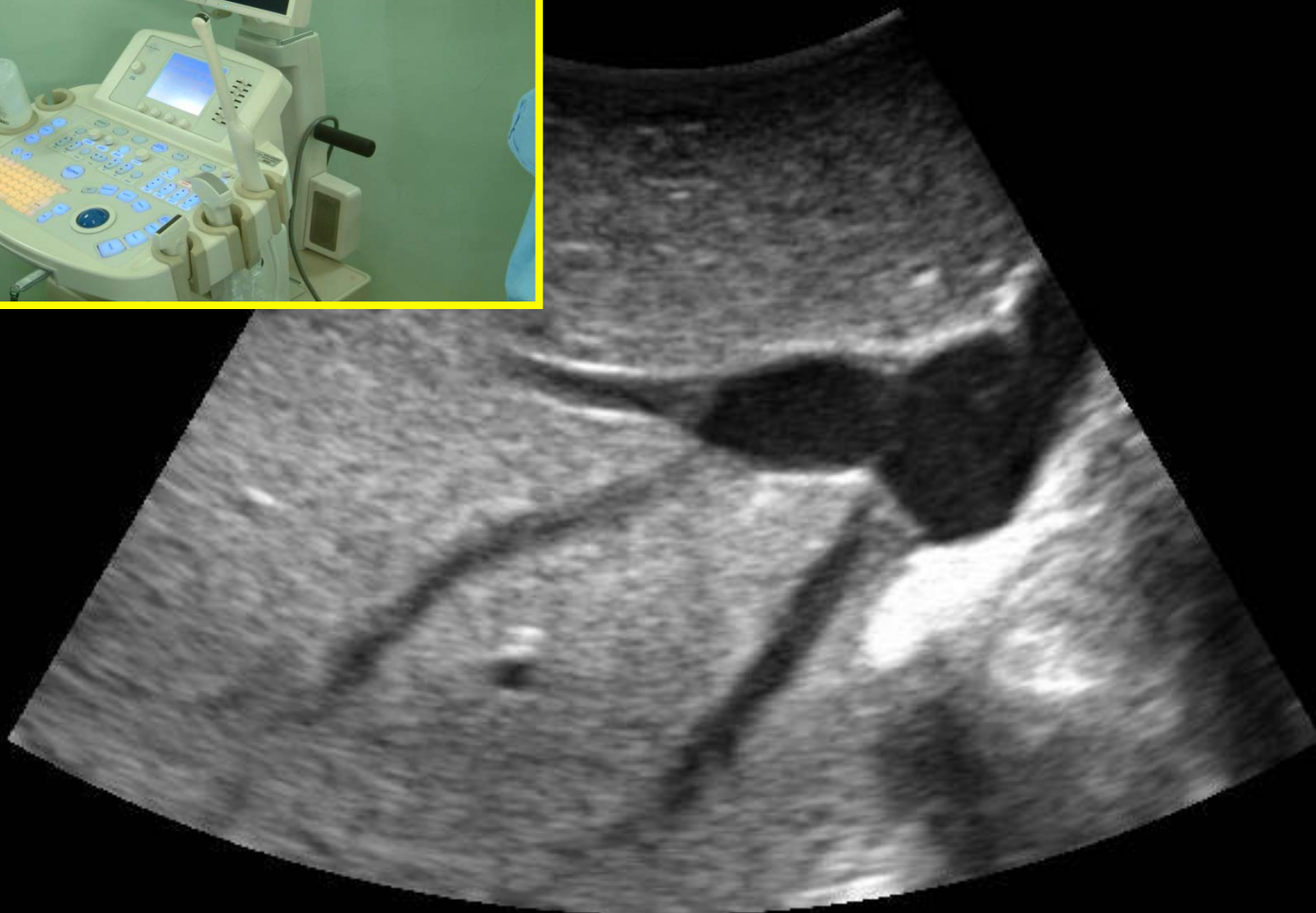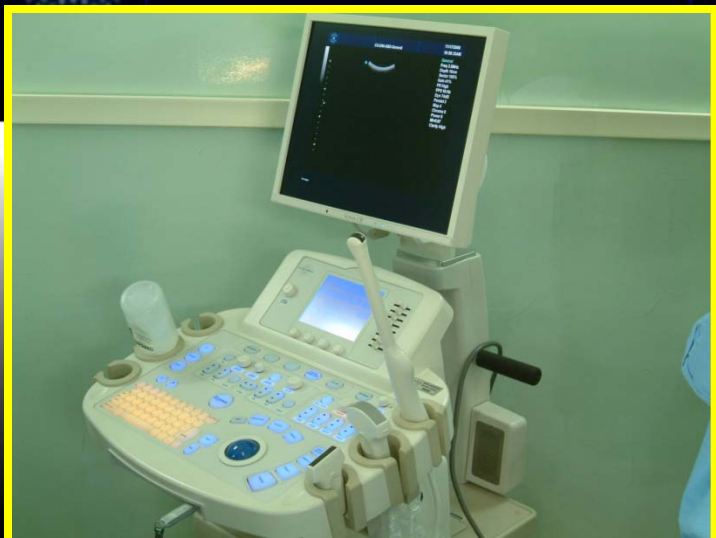Map 4

Chroma 0

Power -2

MI<0.97

Clarity High



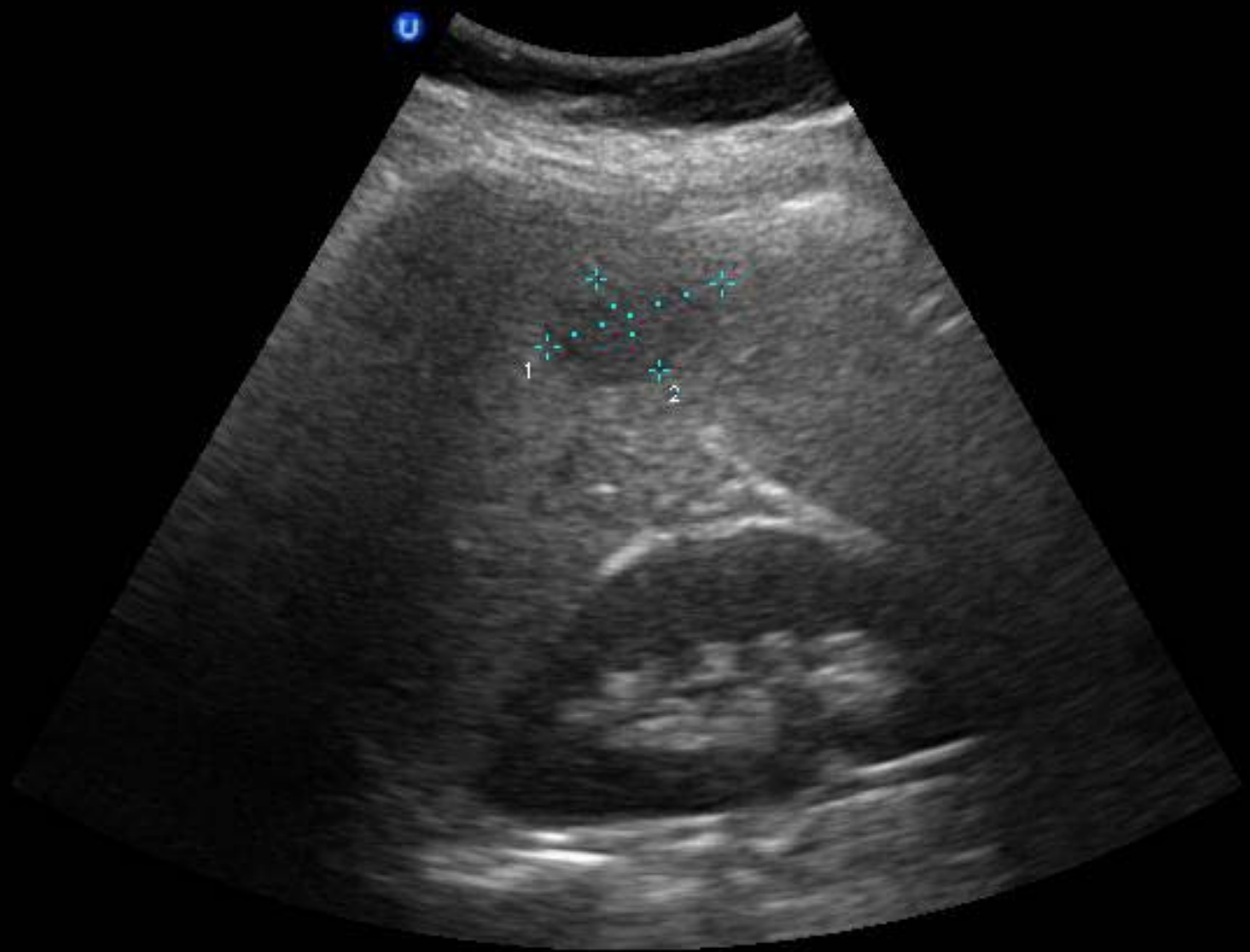


CRISTIANA

HUGG
C5-2/60-ABD-[ABDOMEN.]

03/16/2009
05:57:50PM

General
Freq 3.3MHz
Depth 16cm
Sector 100%
Gain 46%
FR High
FPS 22 Hz
Dyn 72dB
Persist 3
Map 4
Chroma 0
Power -2
MI<0.92
Clarity High



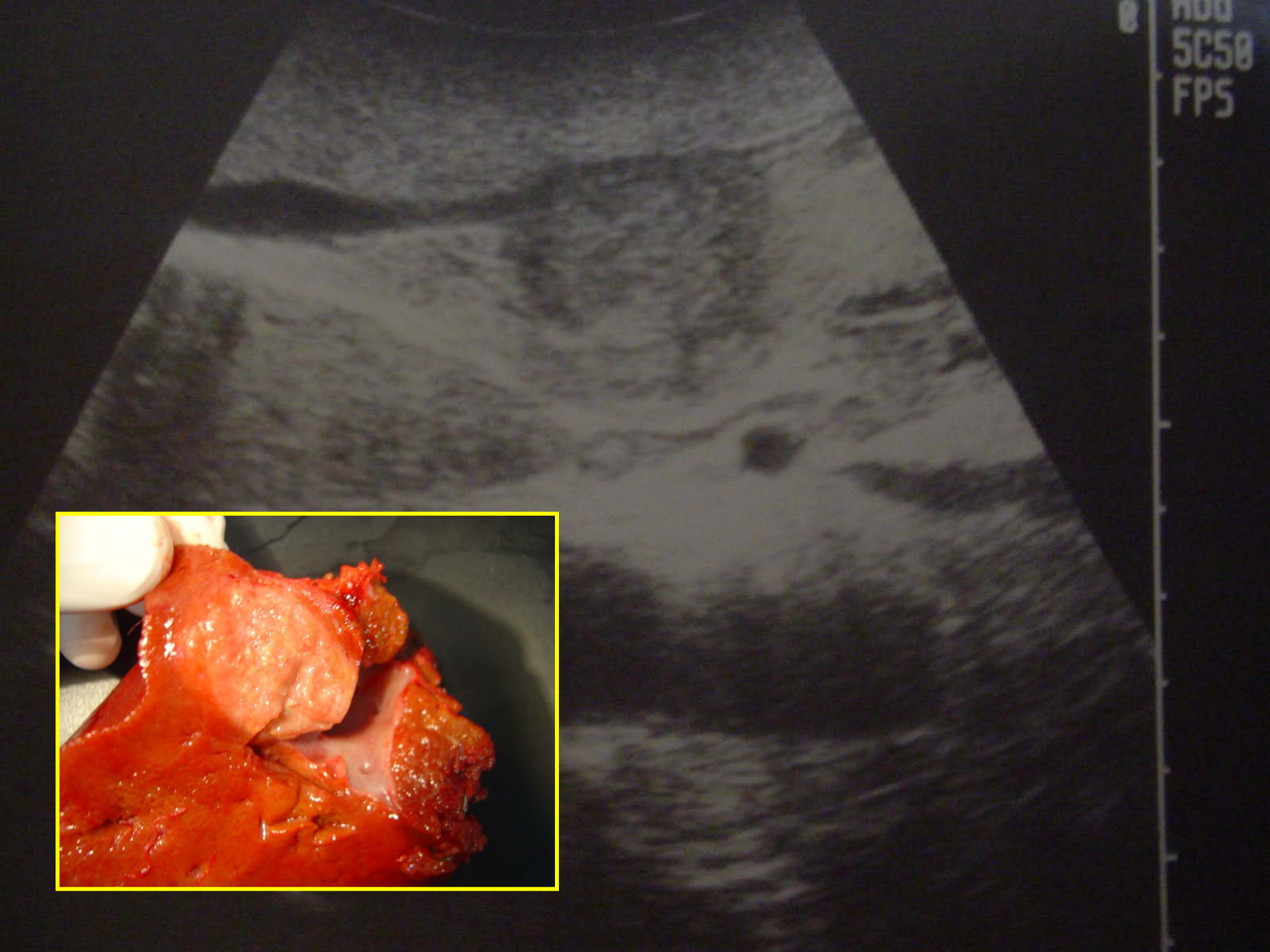
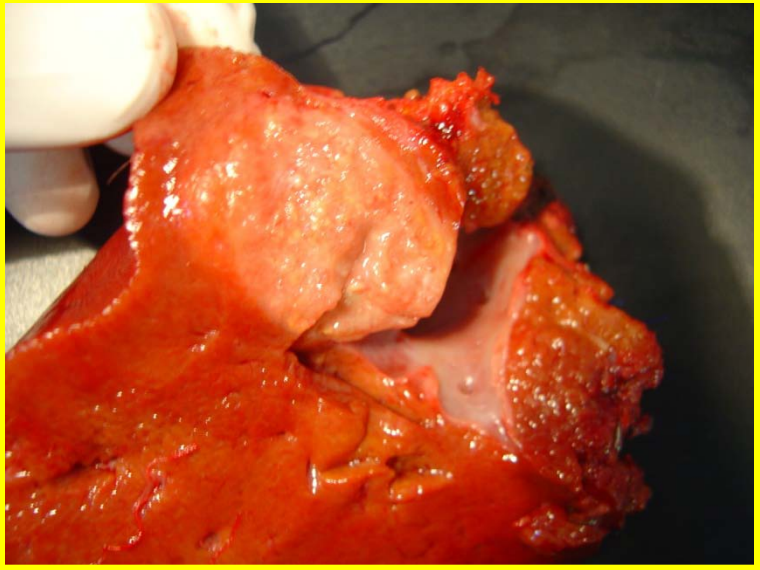
1 Dist 32.76 mm
2 Dist 19.50 mm

1198 / 1198

[1 ... 1198]



8
ADD
5050
FPS



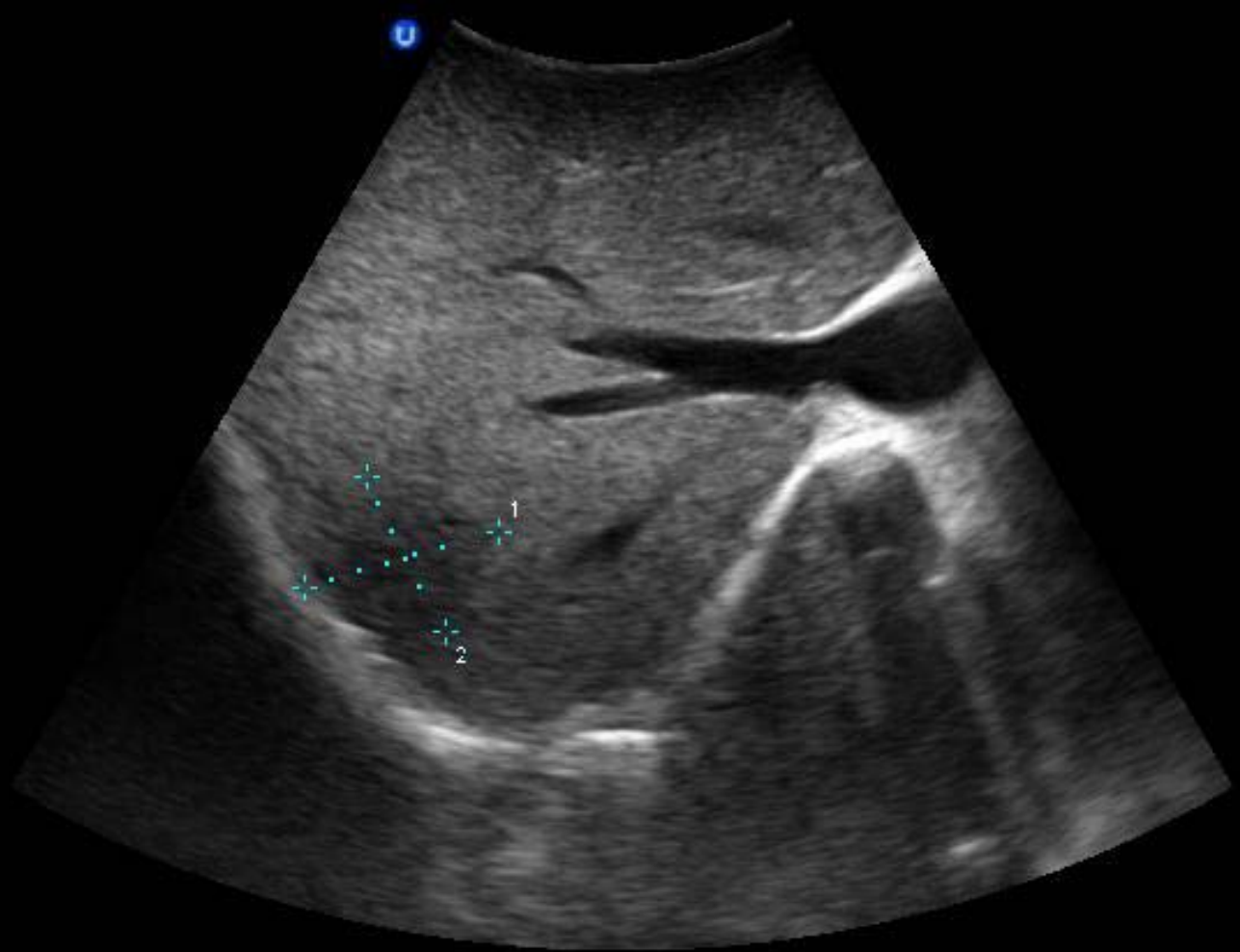

gerson

HUGG
C5-2/60-ABD-[ABDOMEN.]

11/30/2009
12:48:25PM

General
Freq 3.3MHz
Depth 16cm
Sector 100%
Gain 46%
FR High
FPS 22 Hz
Dyn 72dB
Persist 3
Map 4
Chroma 0
Power -2
MI<0.92
Clarity High



1 Dist 35.91 mm
2 Dist 30.88 mm

143 / 143

[1 ... 143]



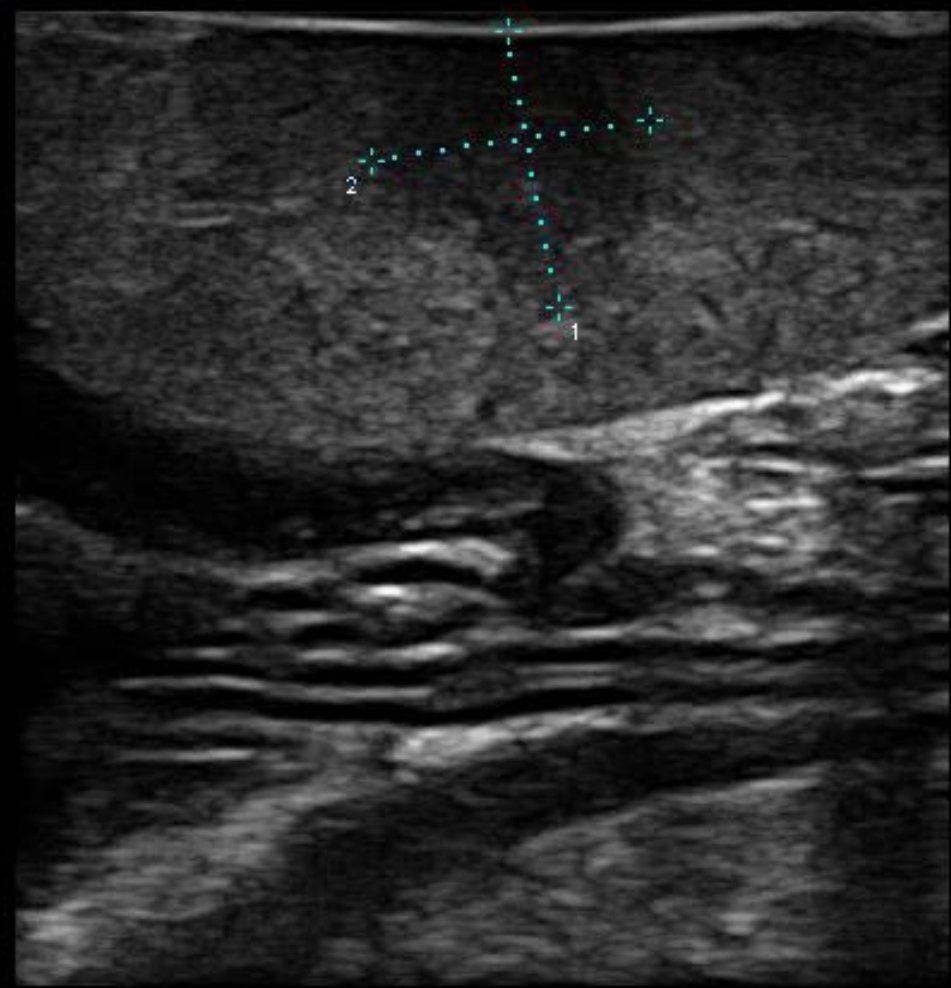


gerson

HUGG
L14-5/38-VA-IJ

11/30/2009
12:41:37PM

General
Freq 10.0MHz
Depth 4.0cm
Sector 100%
Gain 57%
FR High
FPS 32 Hz
Dyn 74dB
Persist 2
Map 7
Chroma 0
Power 0
MI<0.86
Clarity High



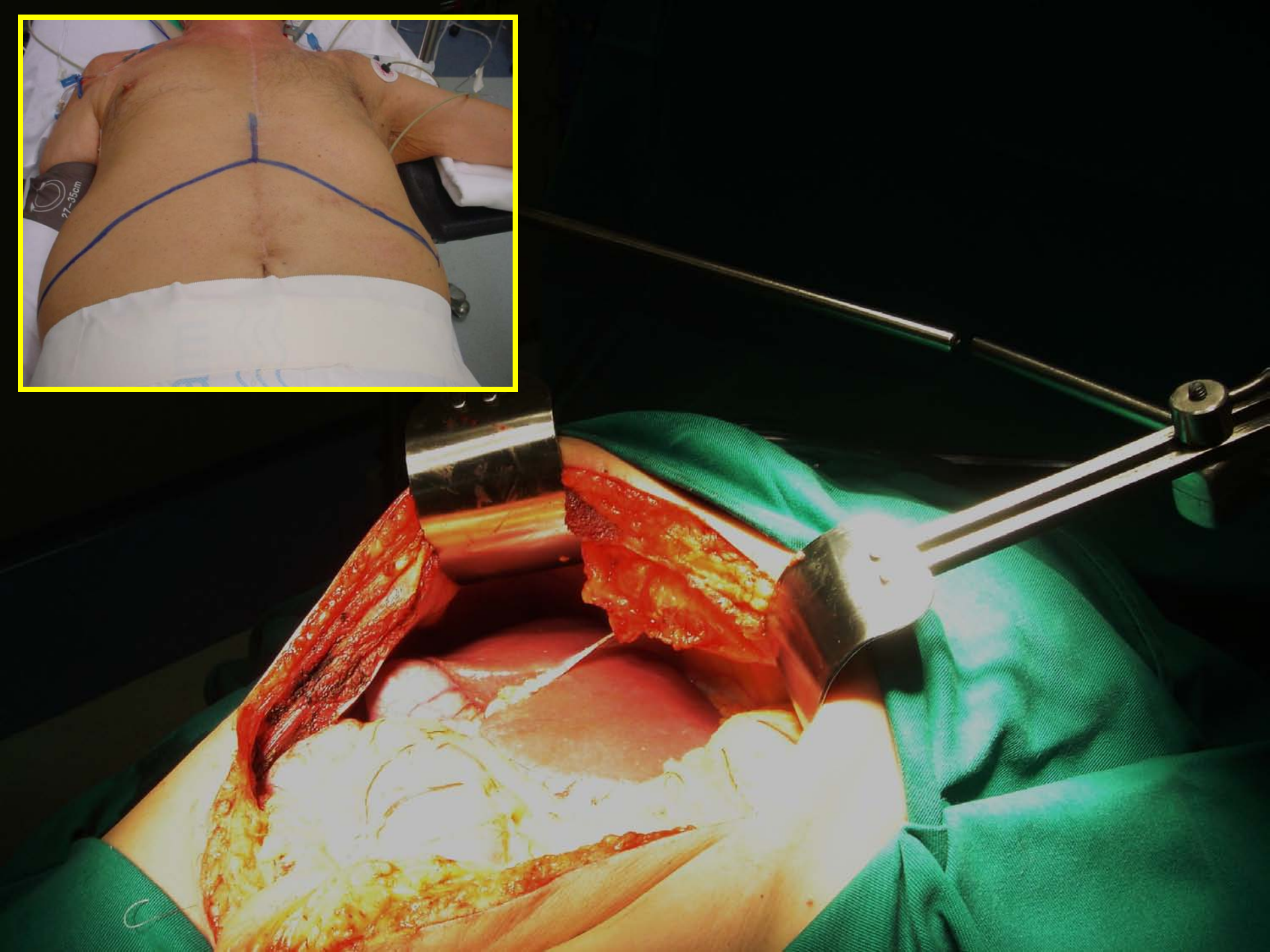
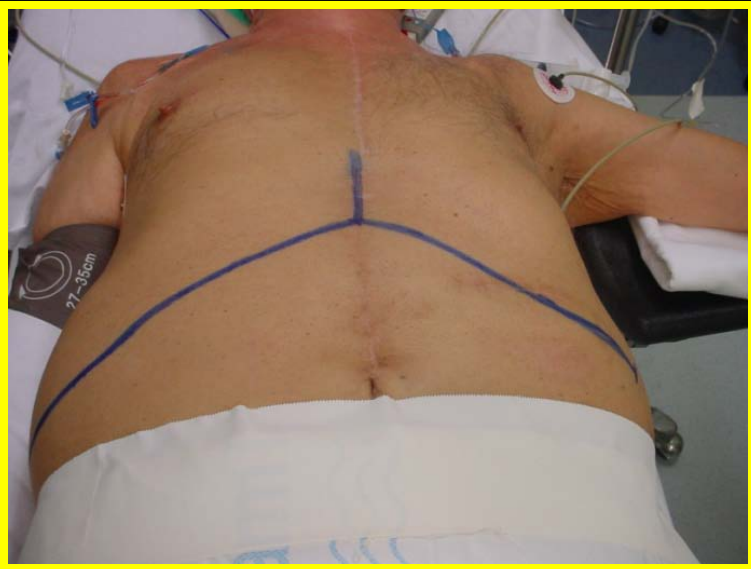1 Dist 11.34 mm
2 Dist 11.37 mm

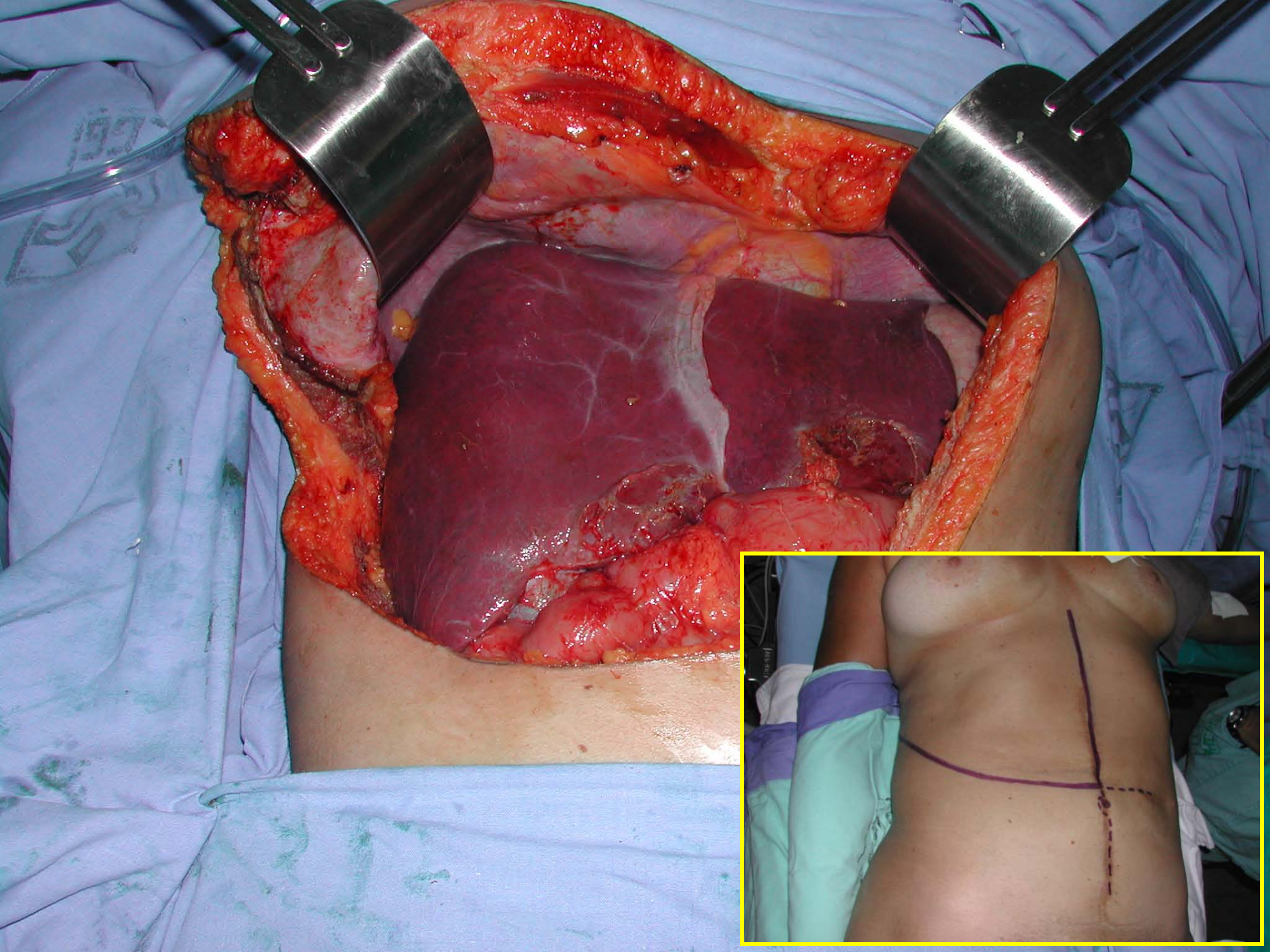
513 / 513

[1 ... 513]



INCISÕES PARA HEPATECTOMIA

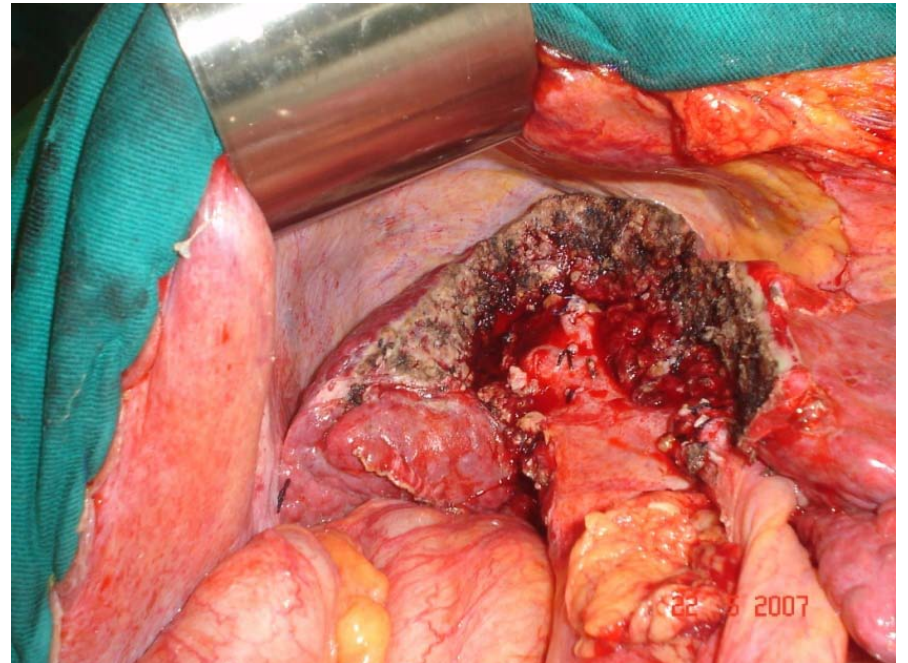
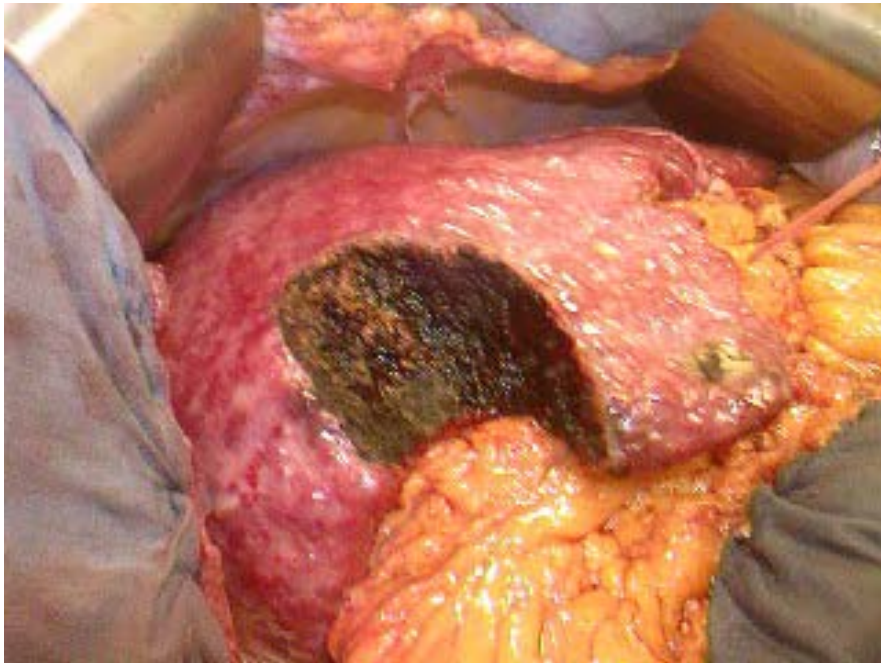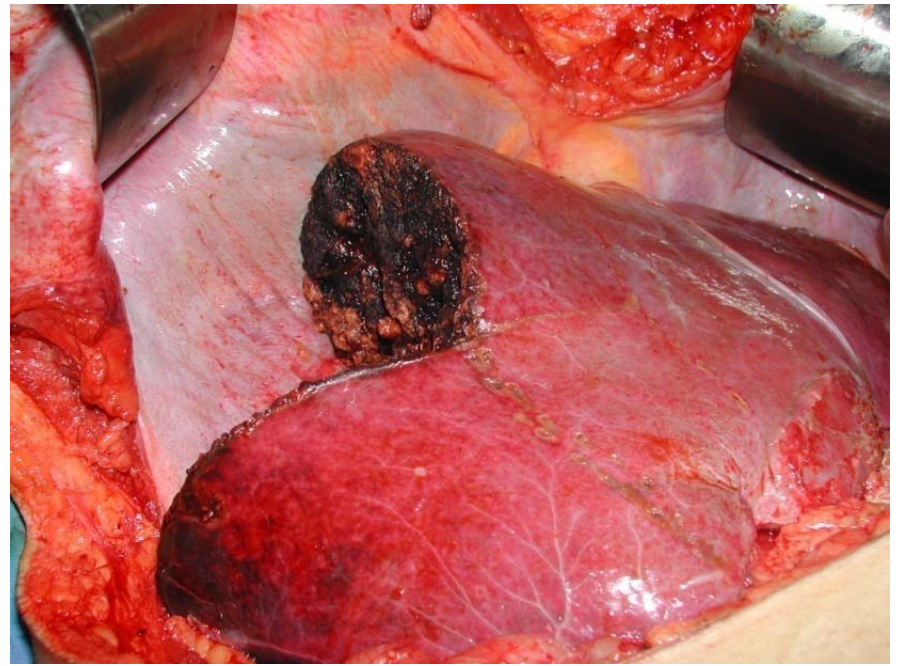
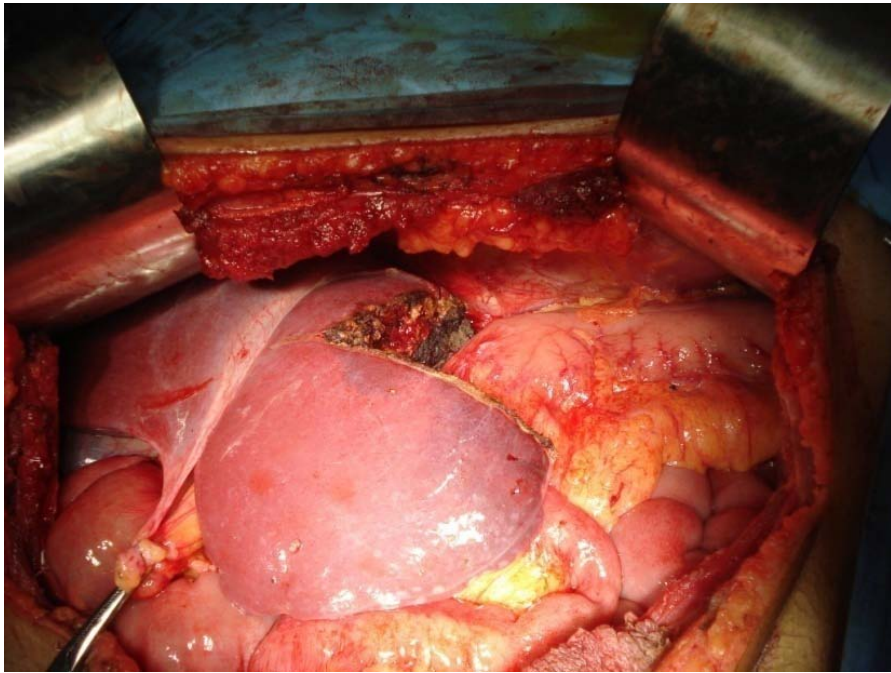


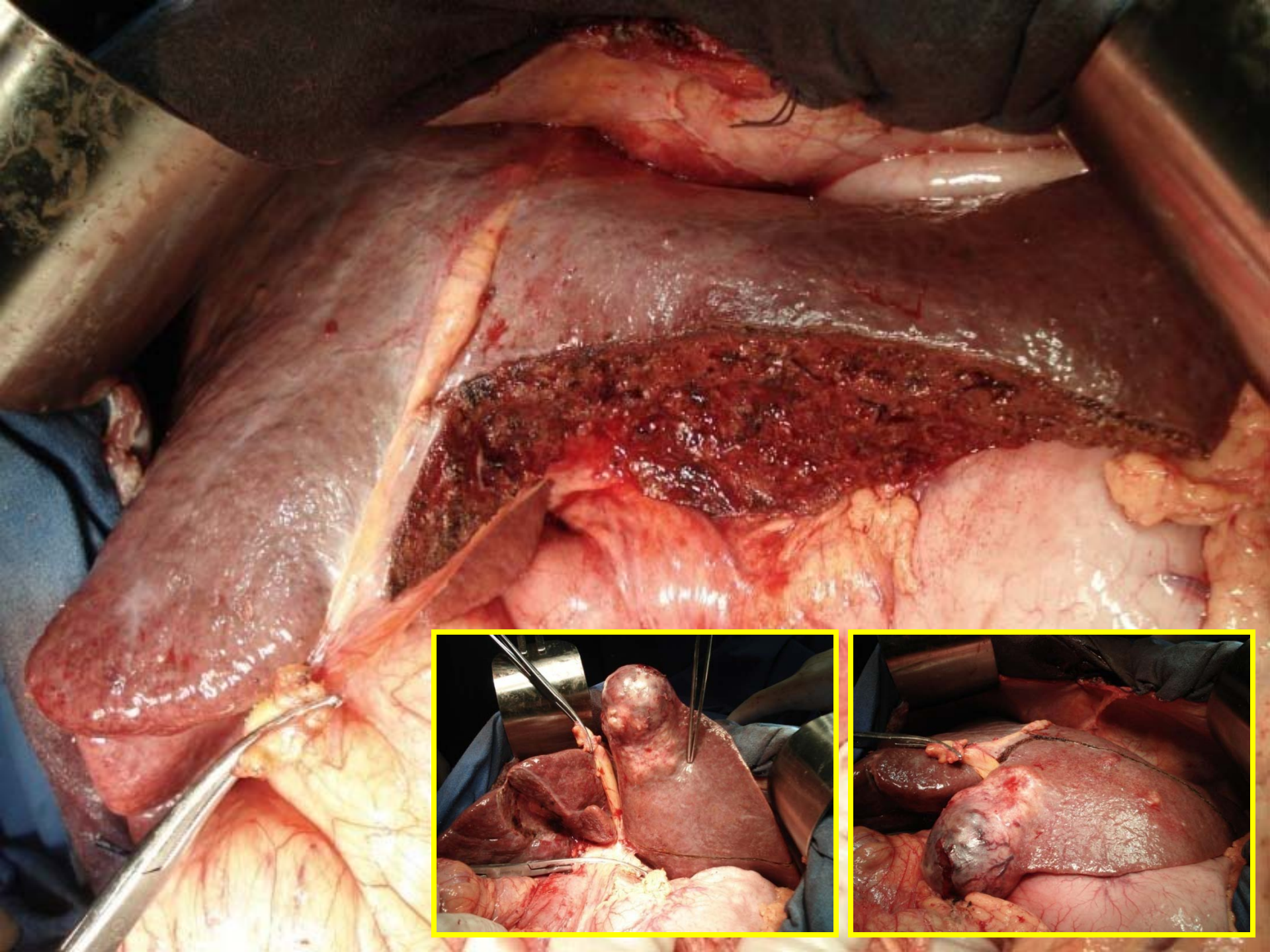


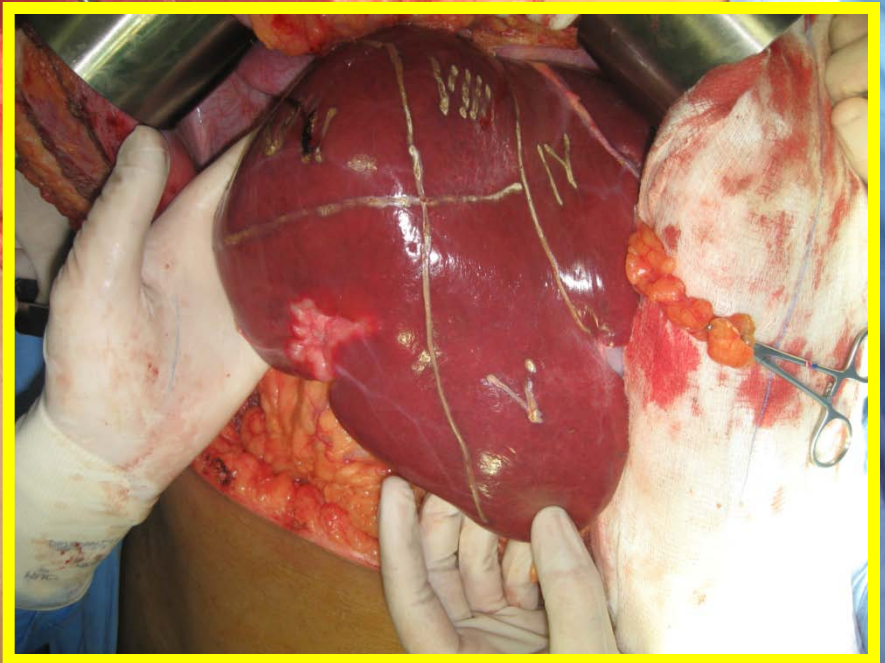
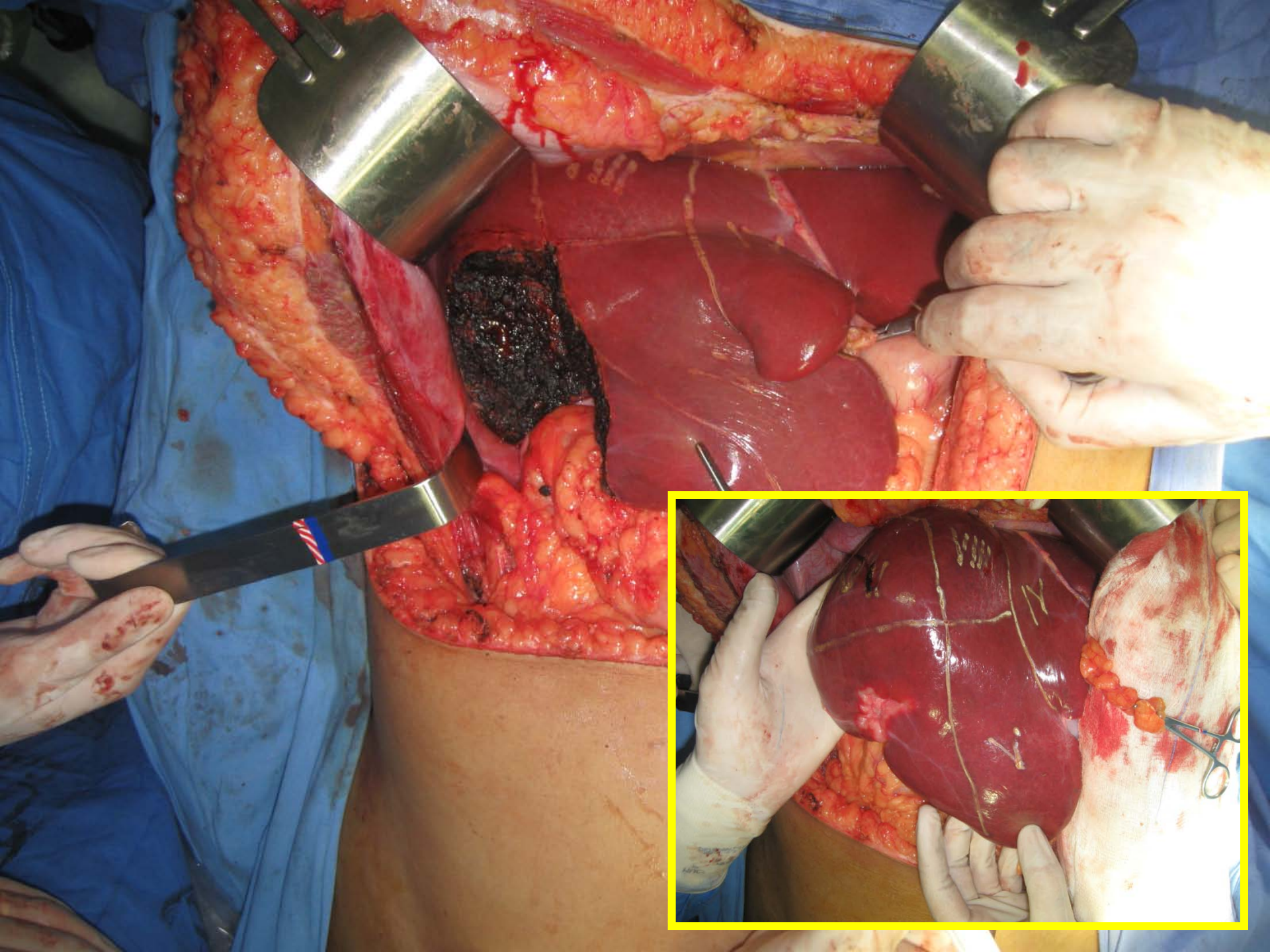
RESSECÇÕES

HEPATECTOMIAS

“Menores”

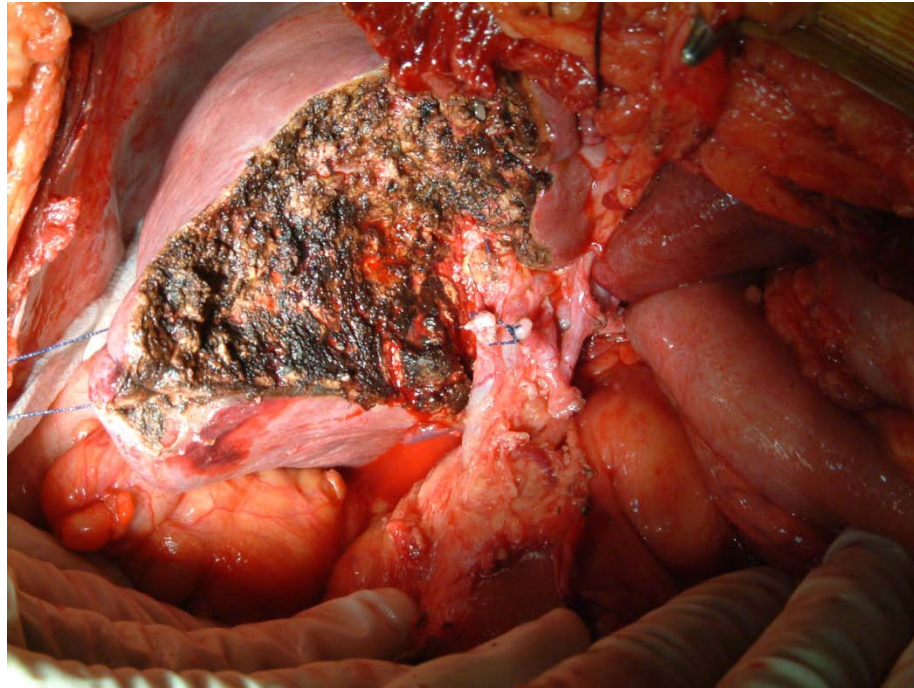
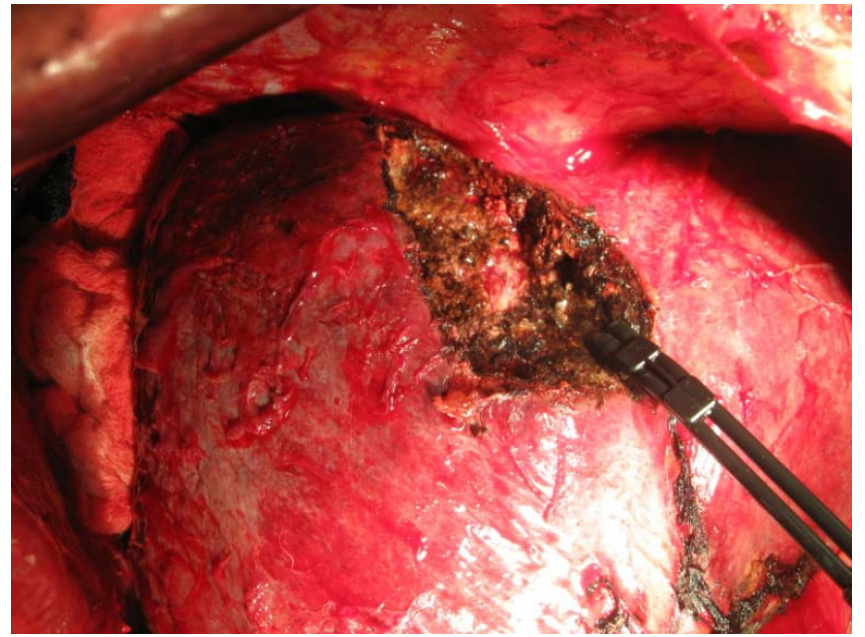
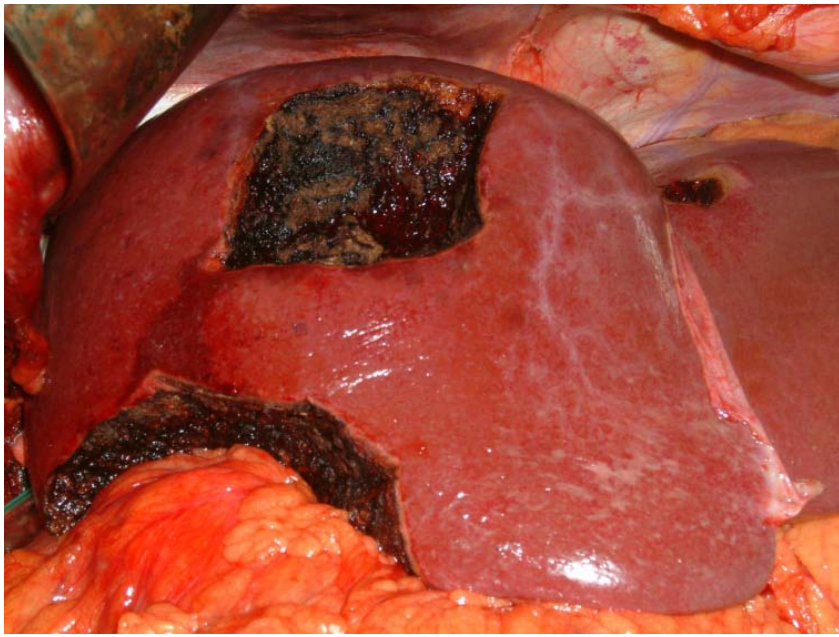


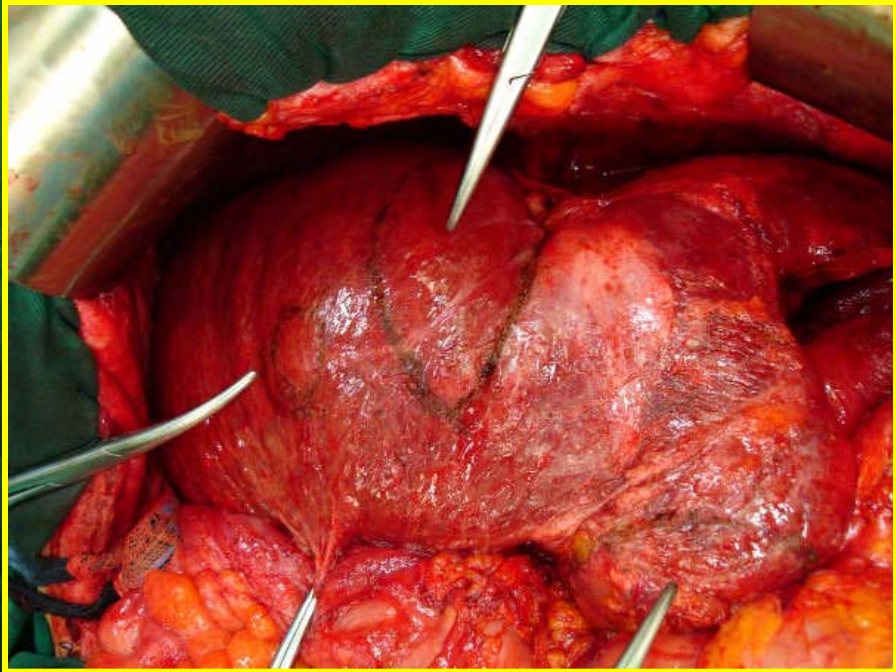
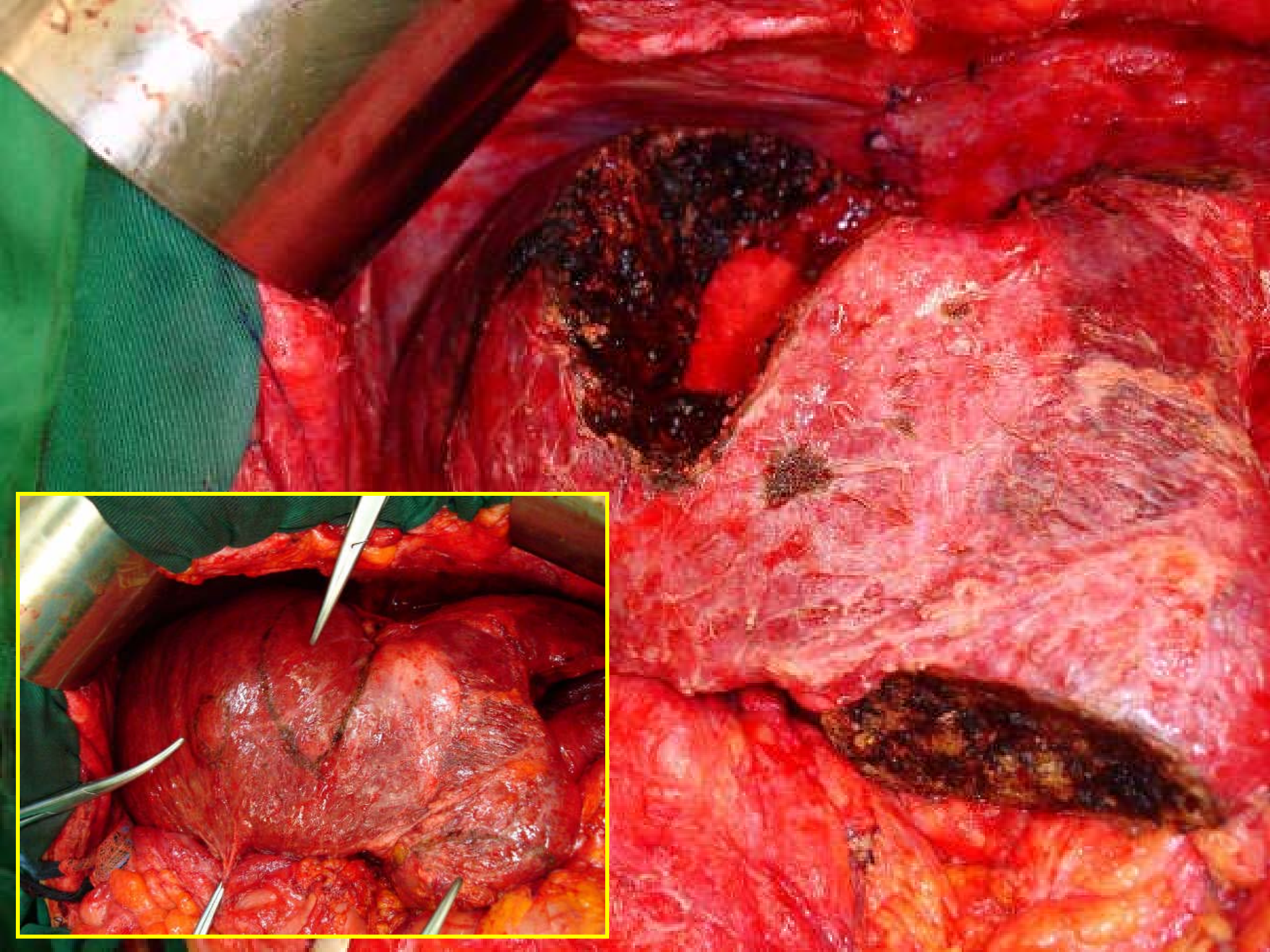




RESSECÇÕES ATÍPICAS

HEPATECTOMIA

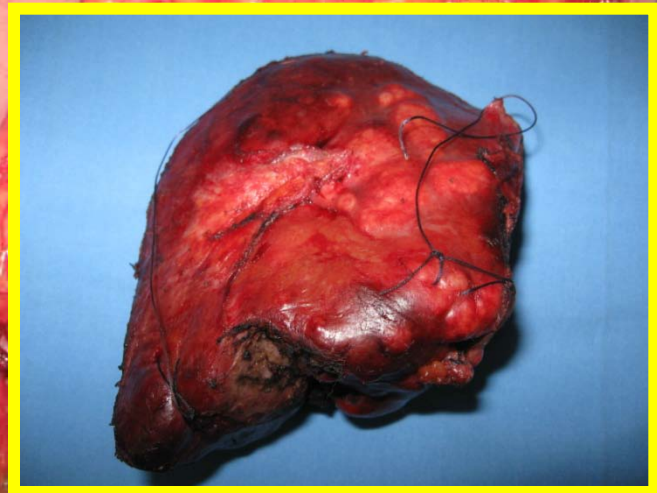
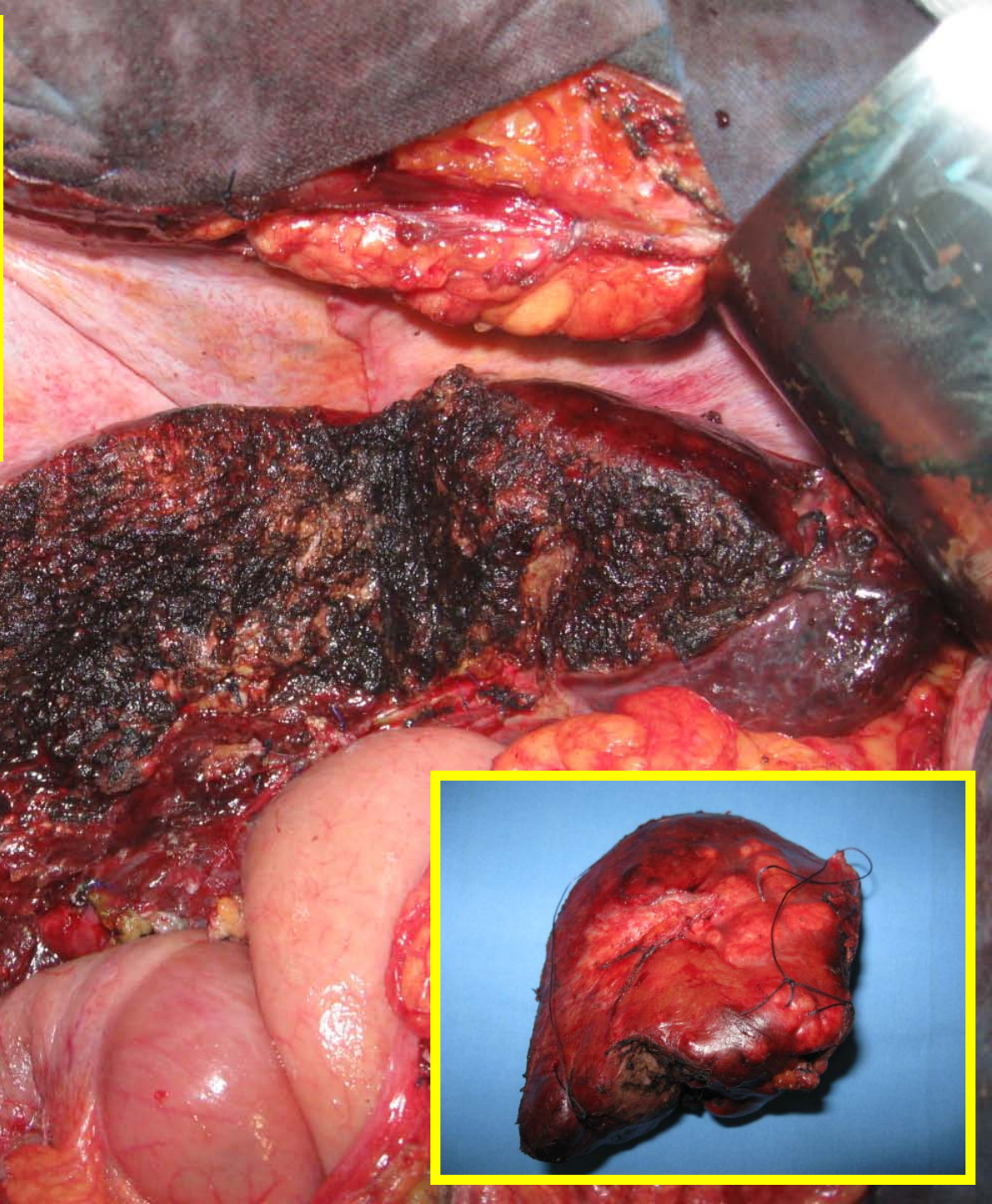
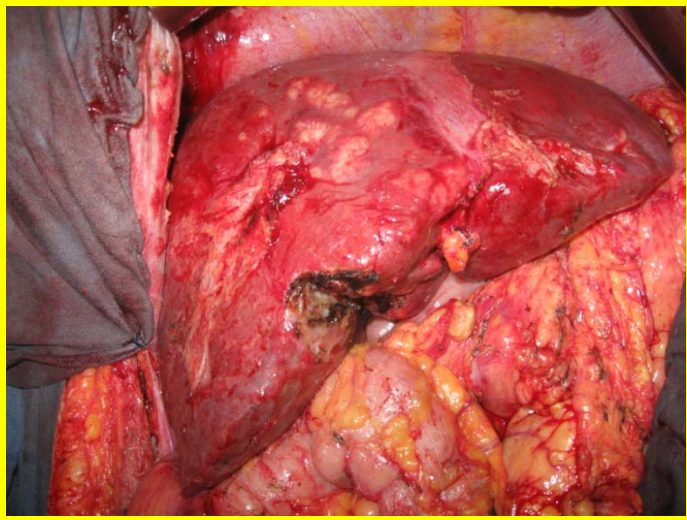




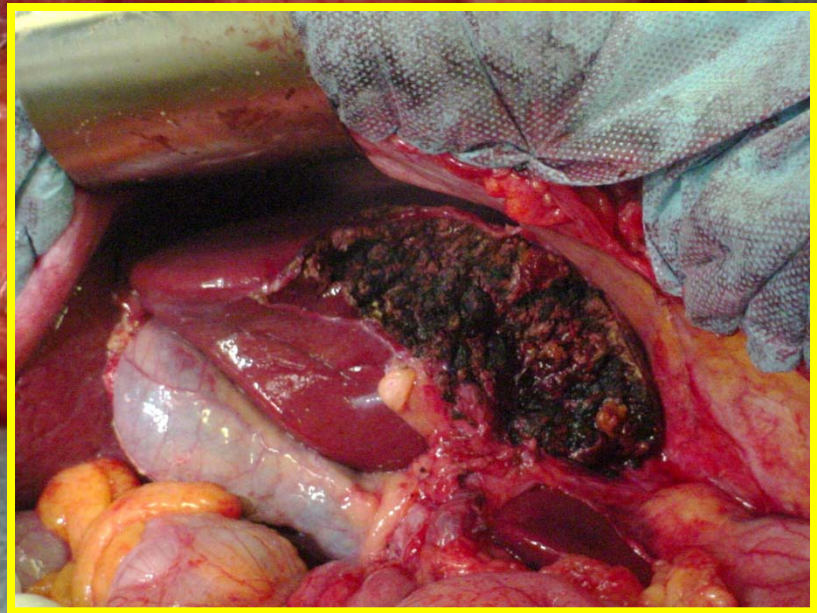
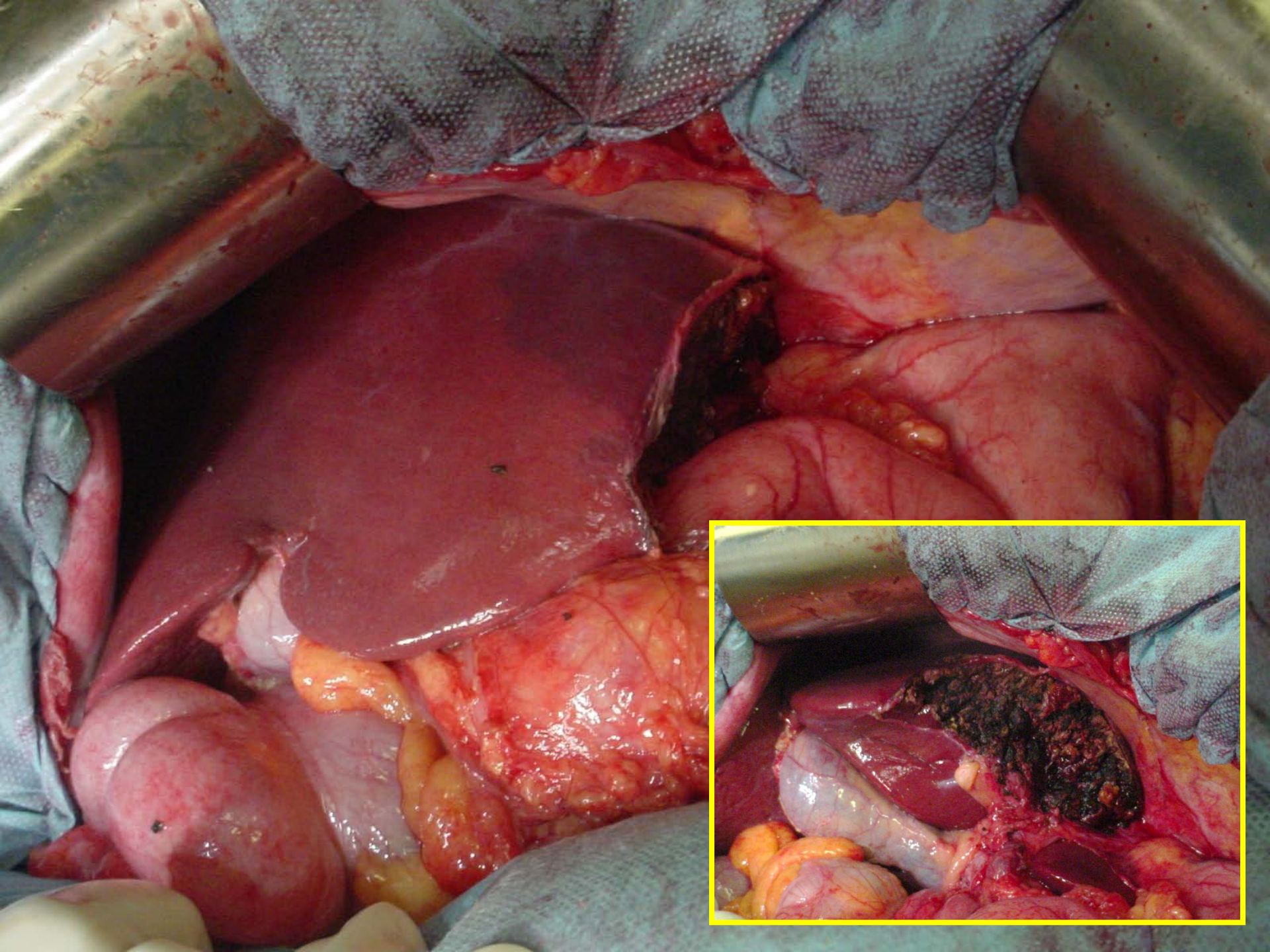
RESSECÇÕES REGRADAS
MAIORES

HEPATECTOMIA

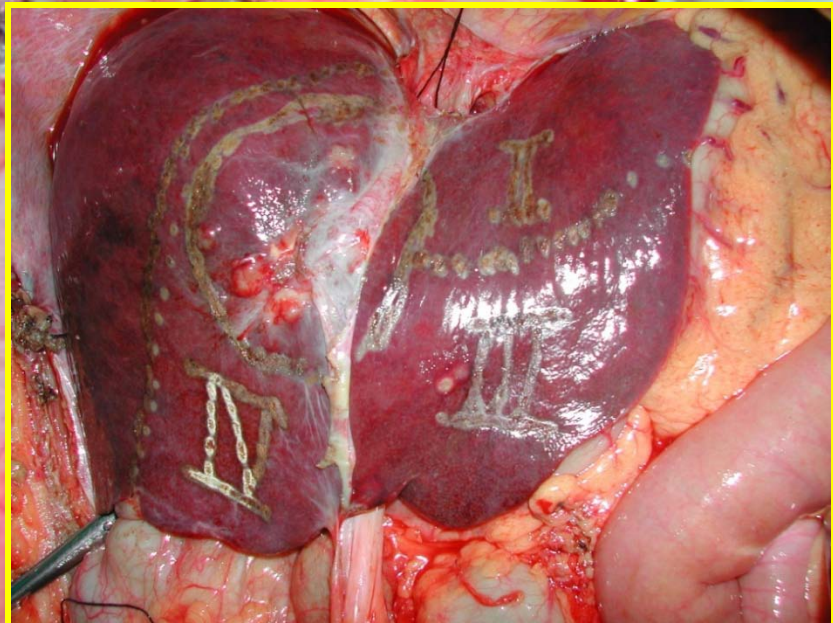
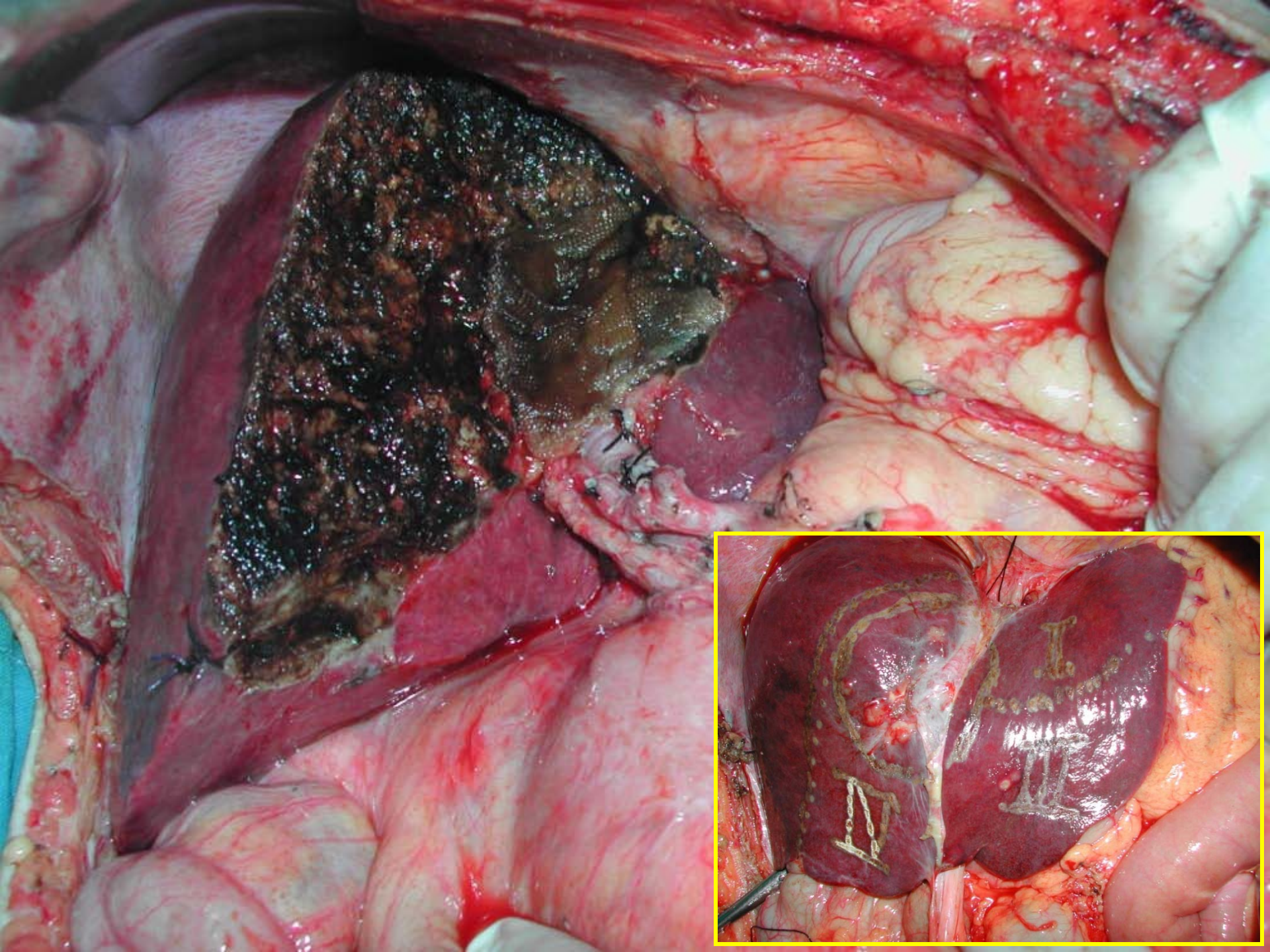
HEPATECTOMIA CENTRAL



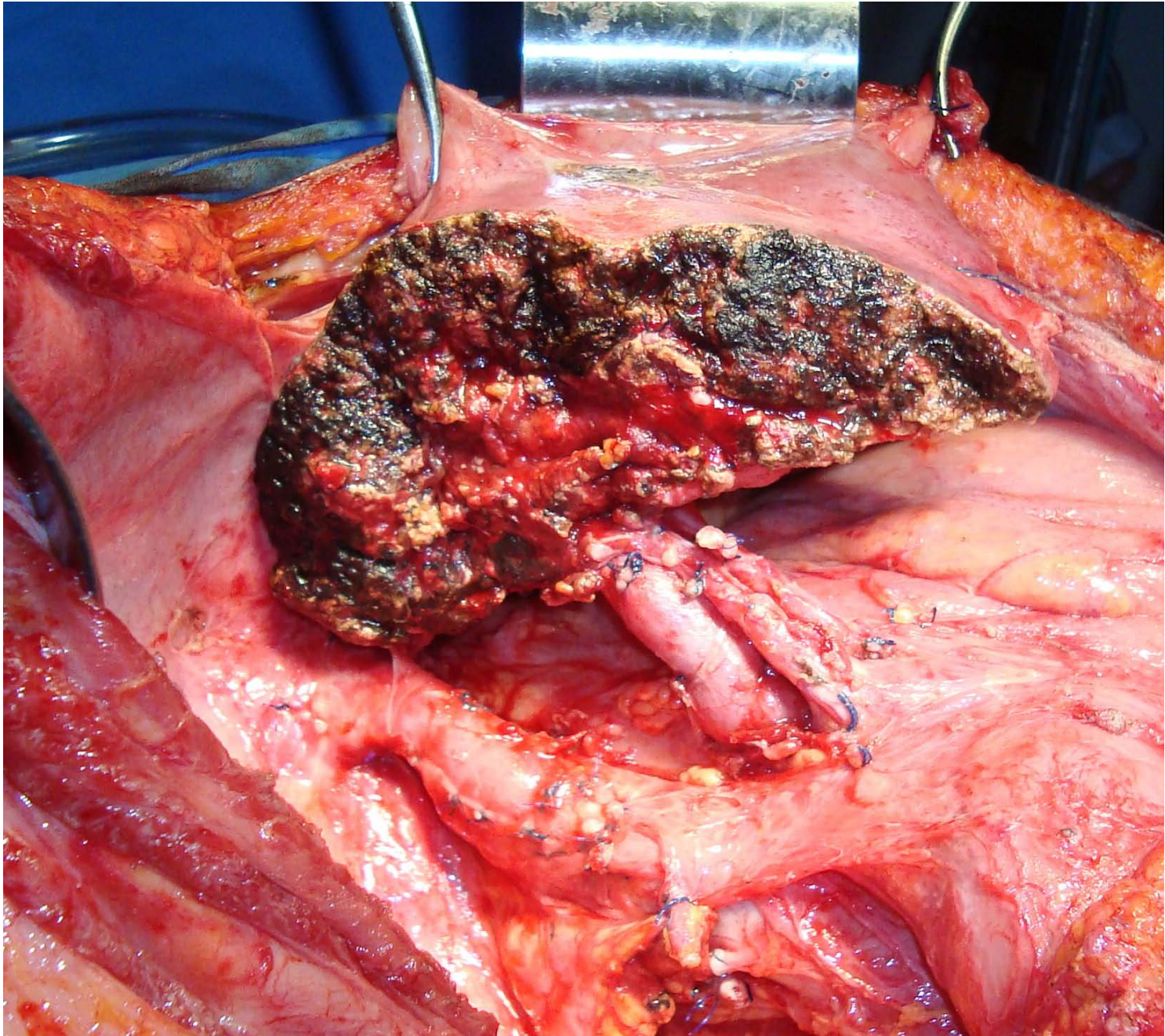
LOBECTOMIA ESQUERDA



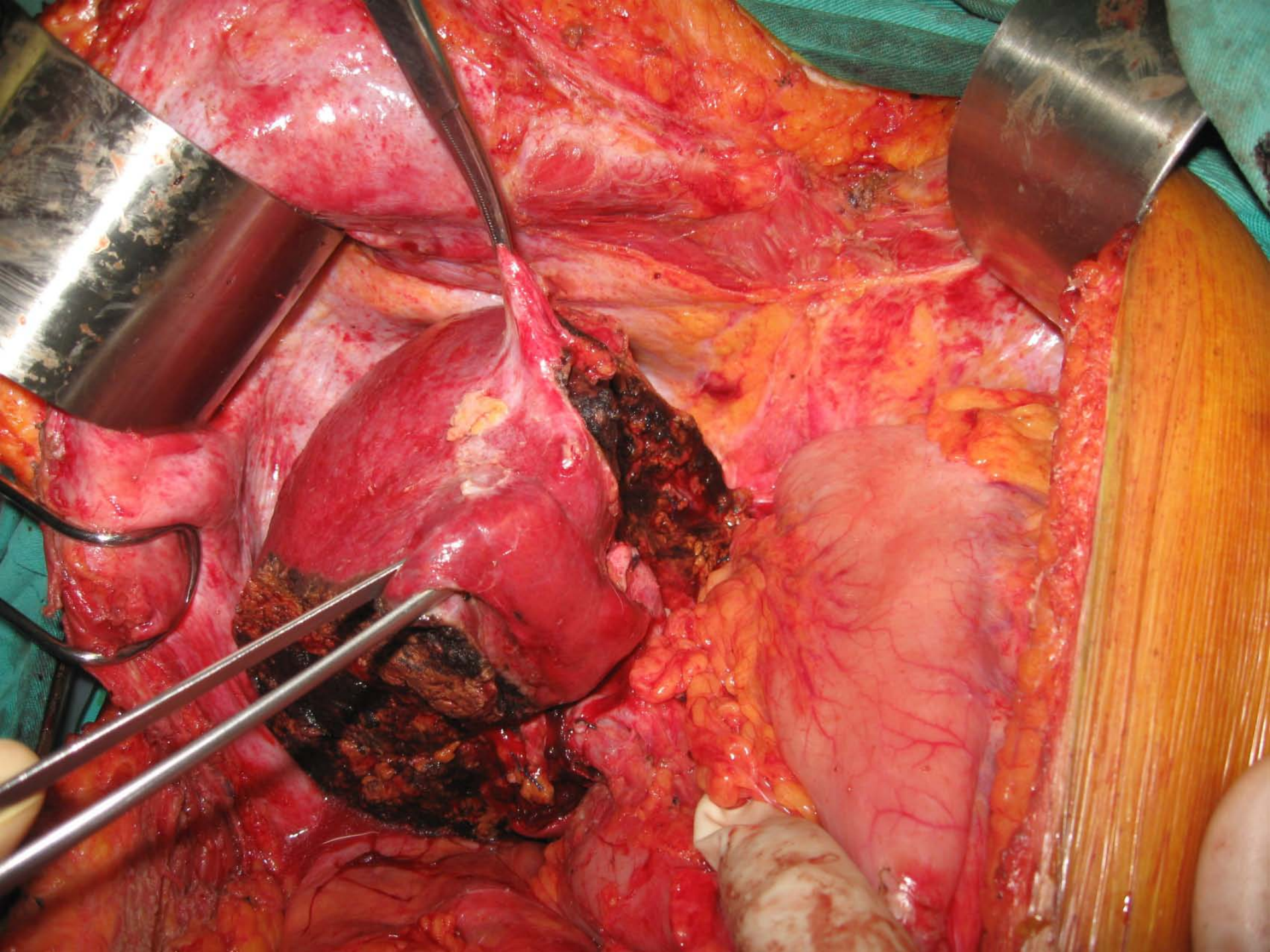
HEPATECTOMIA ESQUERDA



HEPATECTOMIA DIREITA + SEGMENTECTOMIA I

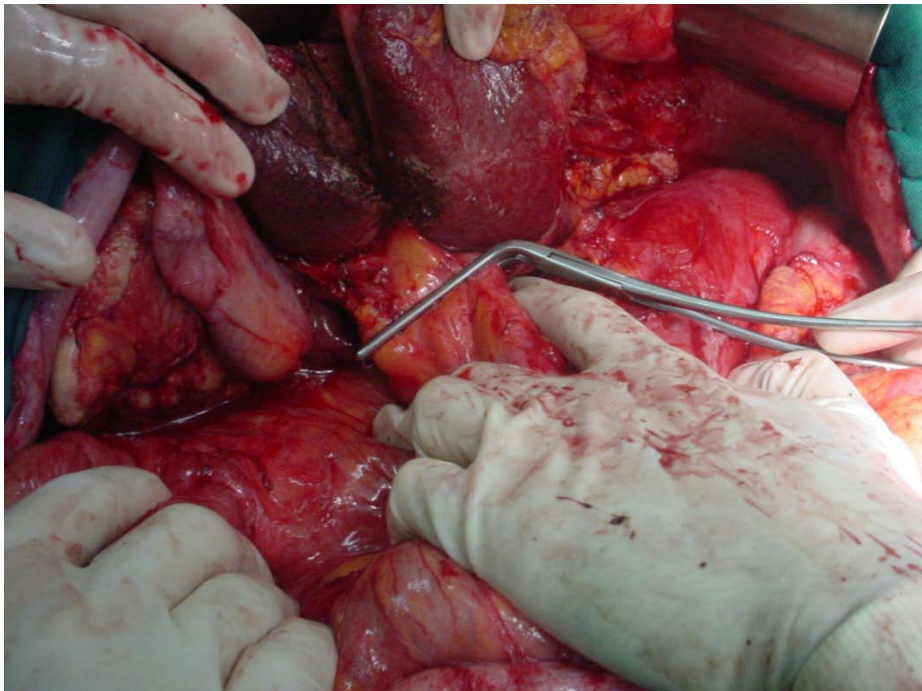
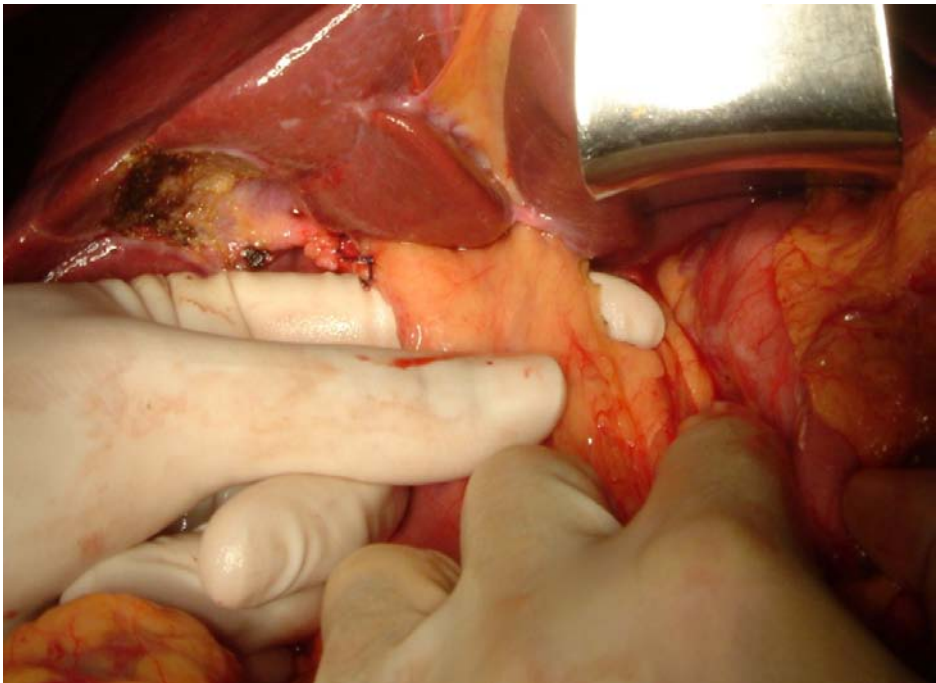
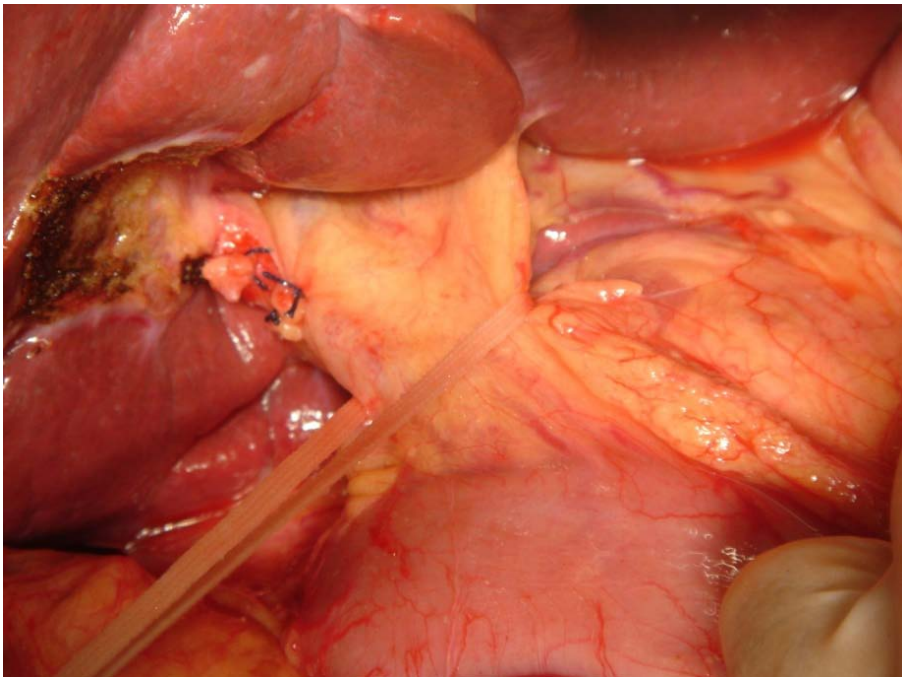


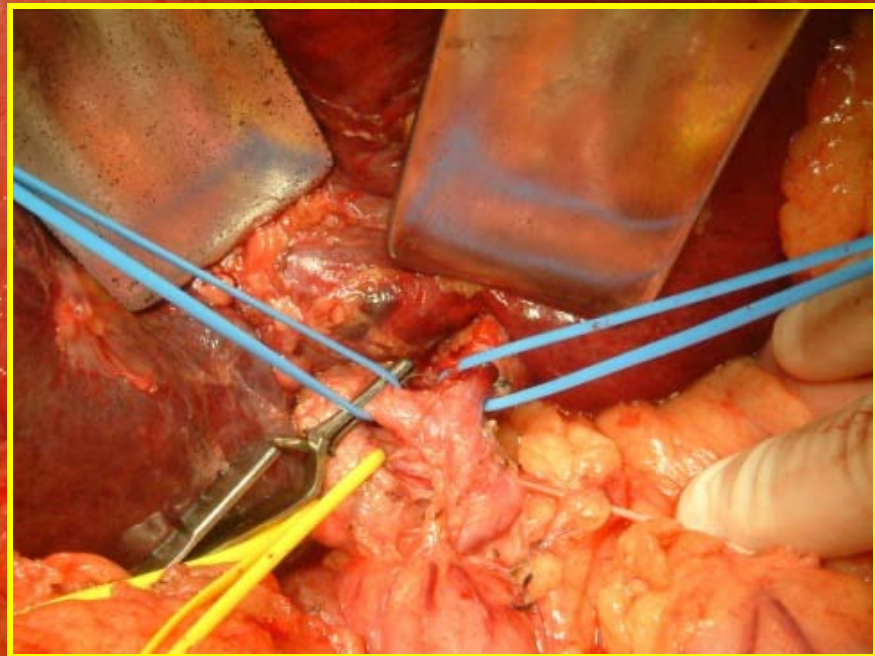
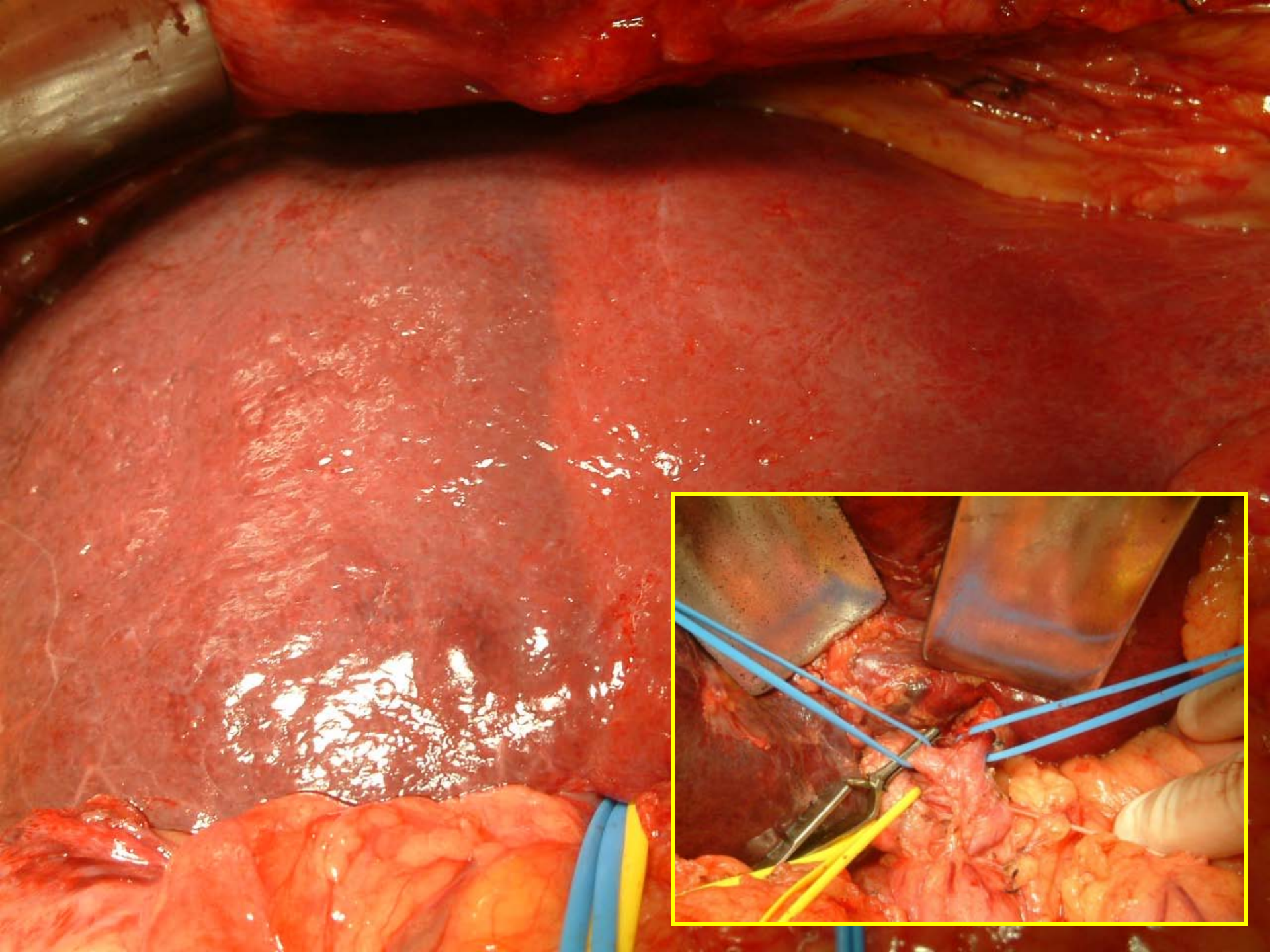
LOBECTOMIA ESQUERDA + BI-
SEGMENTECTOMIA V e VI

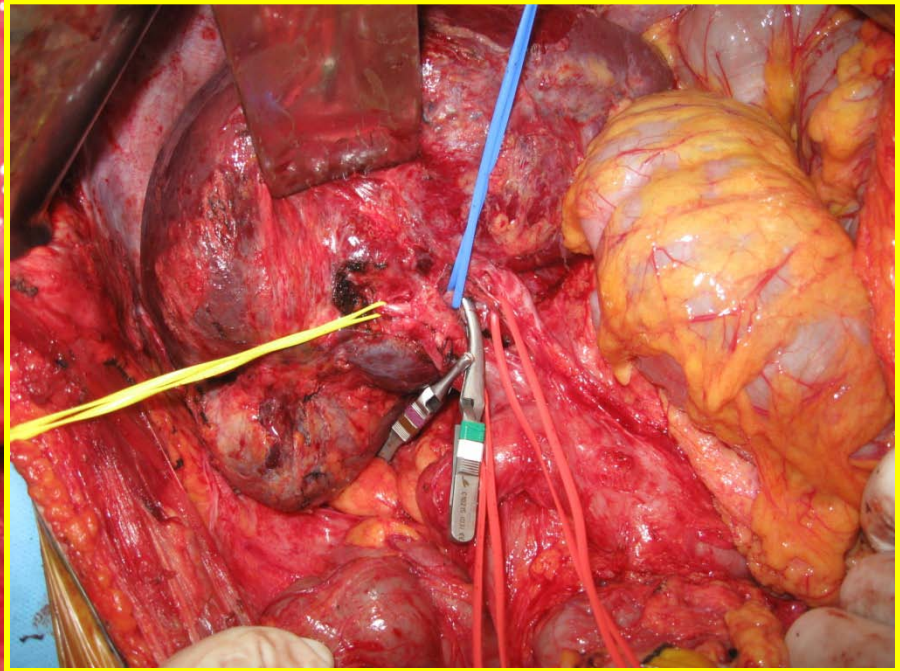
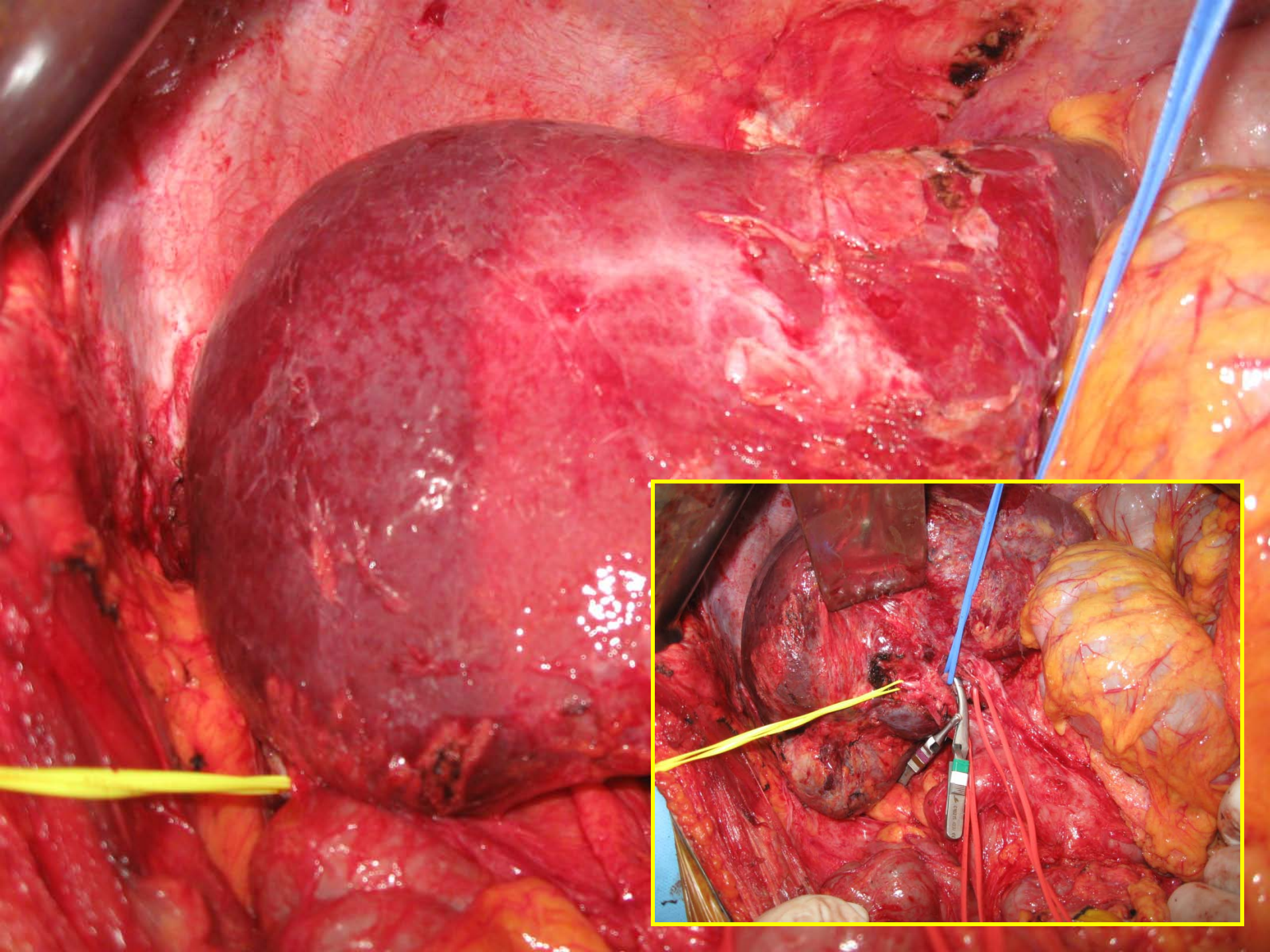


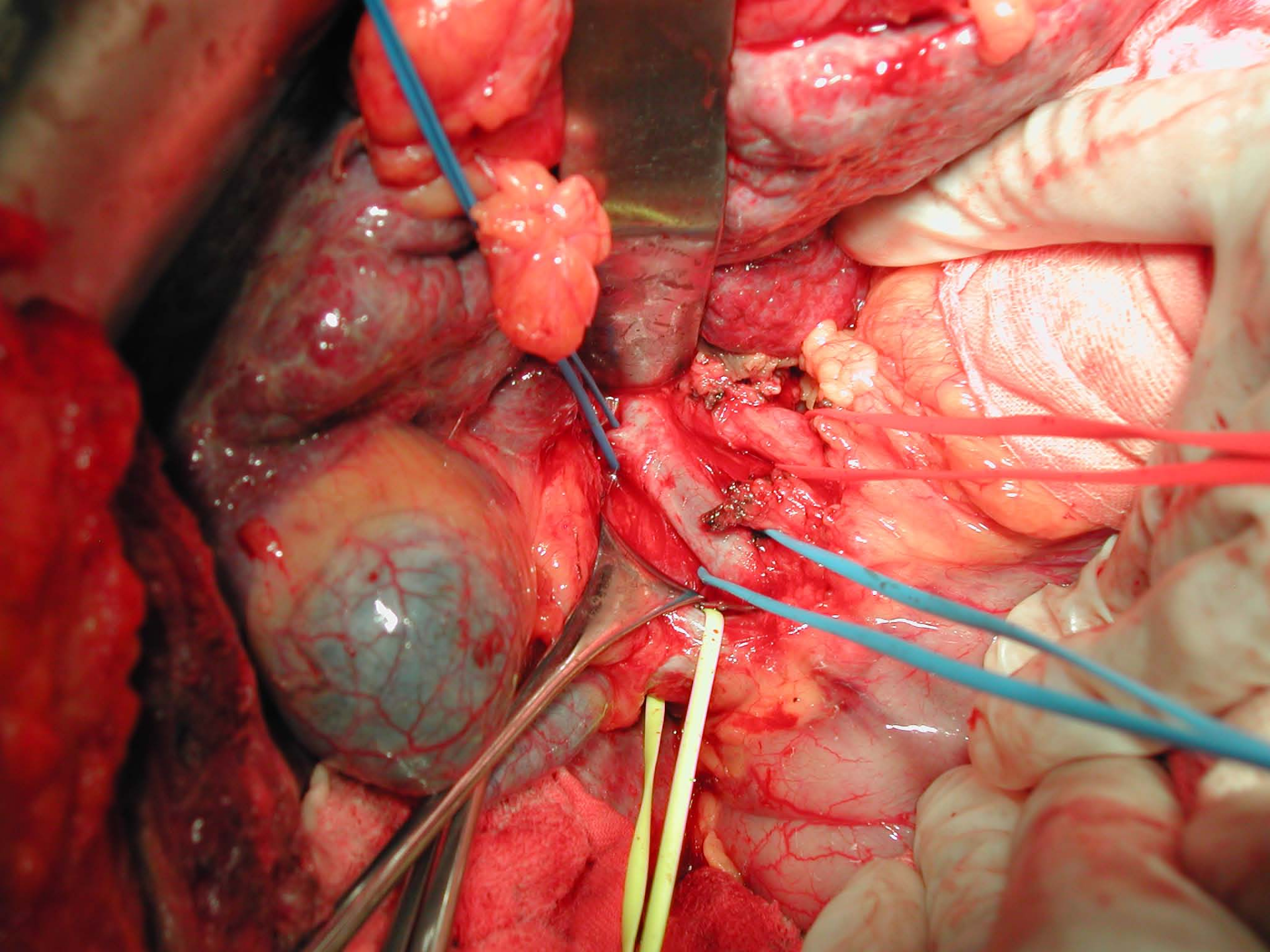
CONTROLE VASCULAR

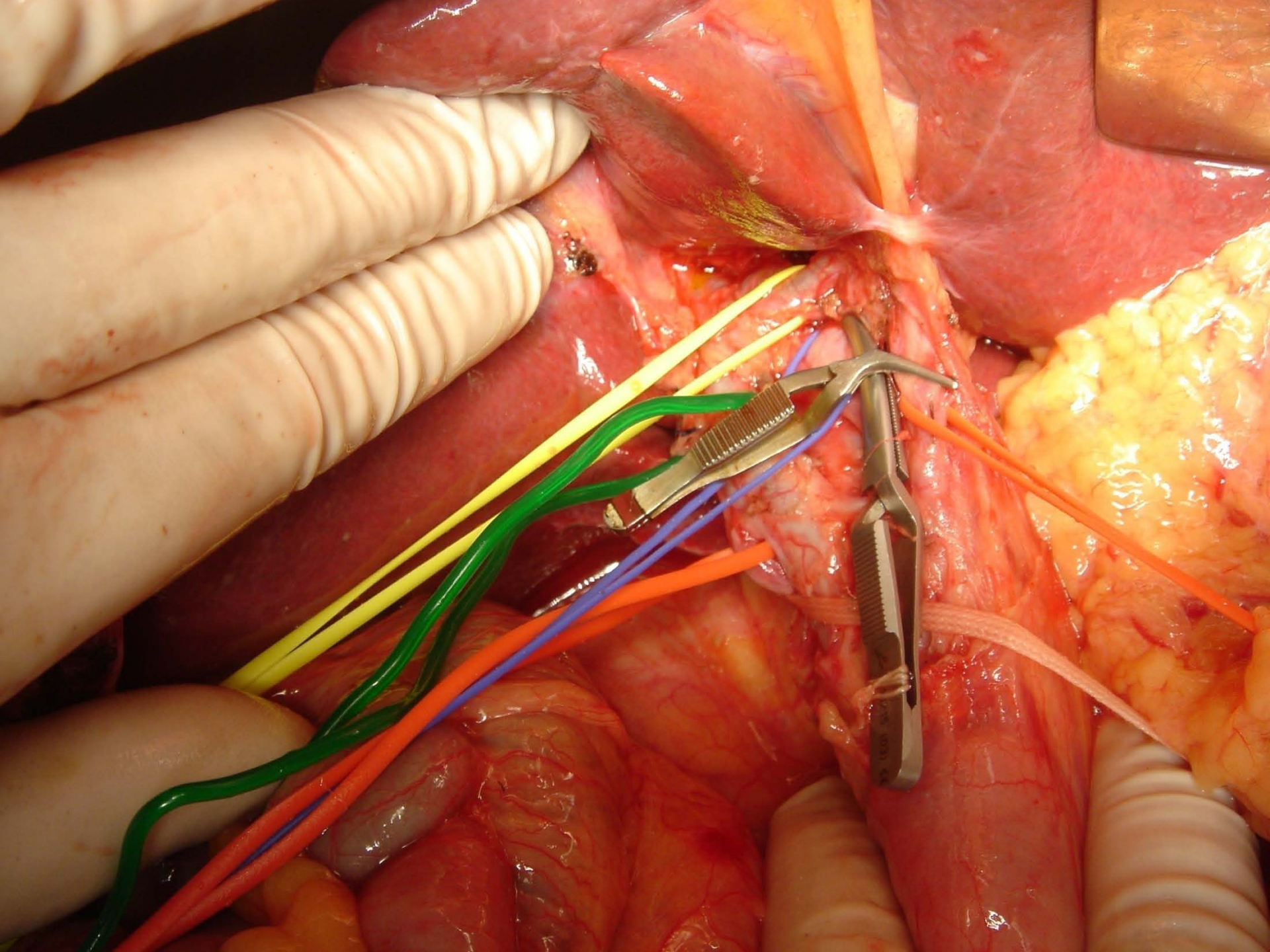
HEPATECTOMIA

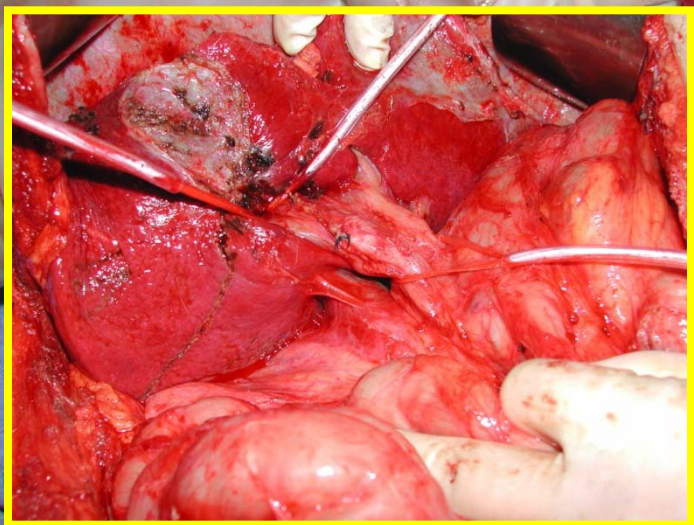
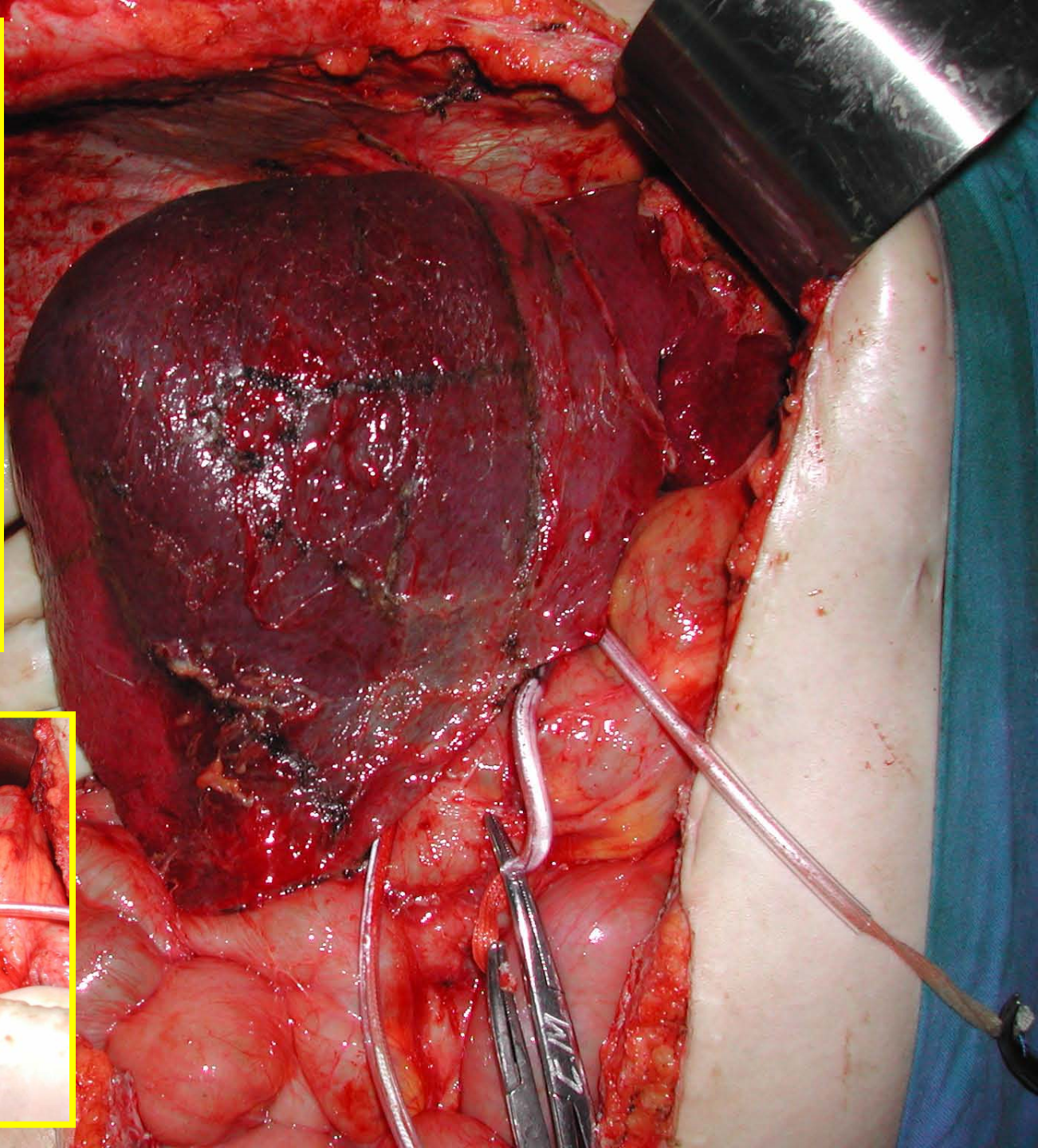
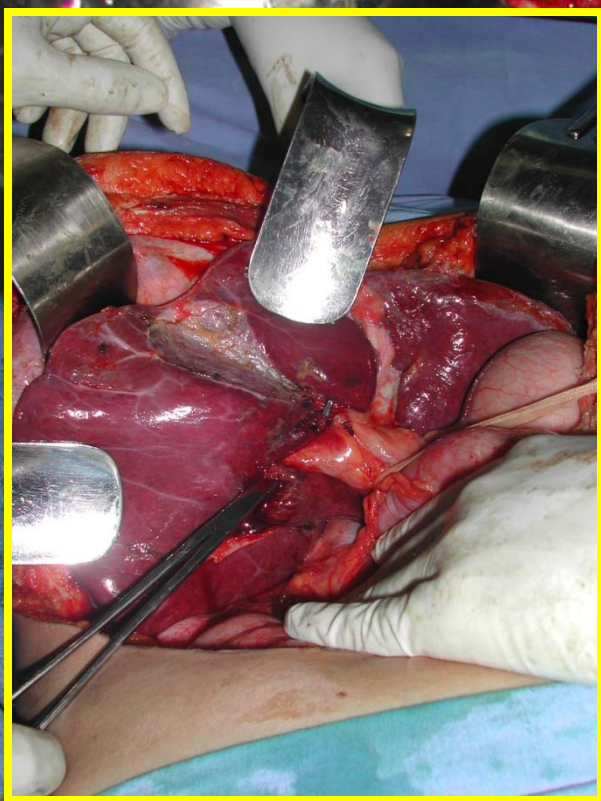


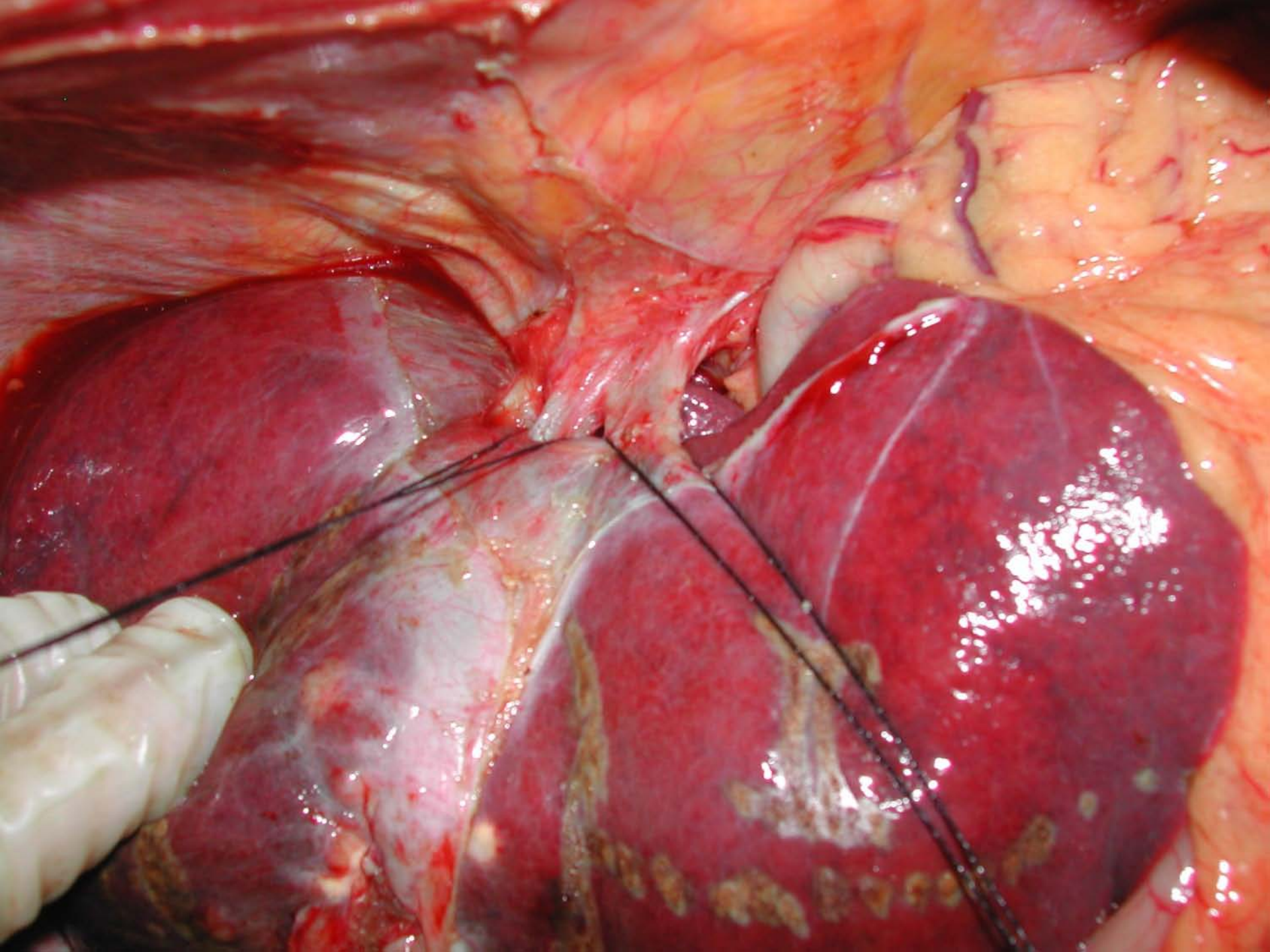






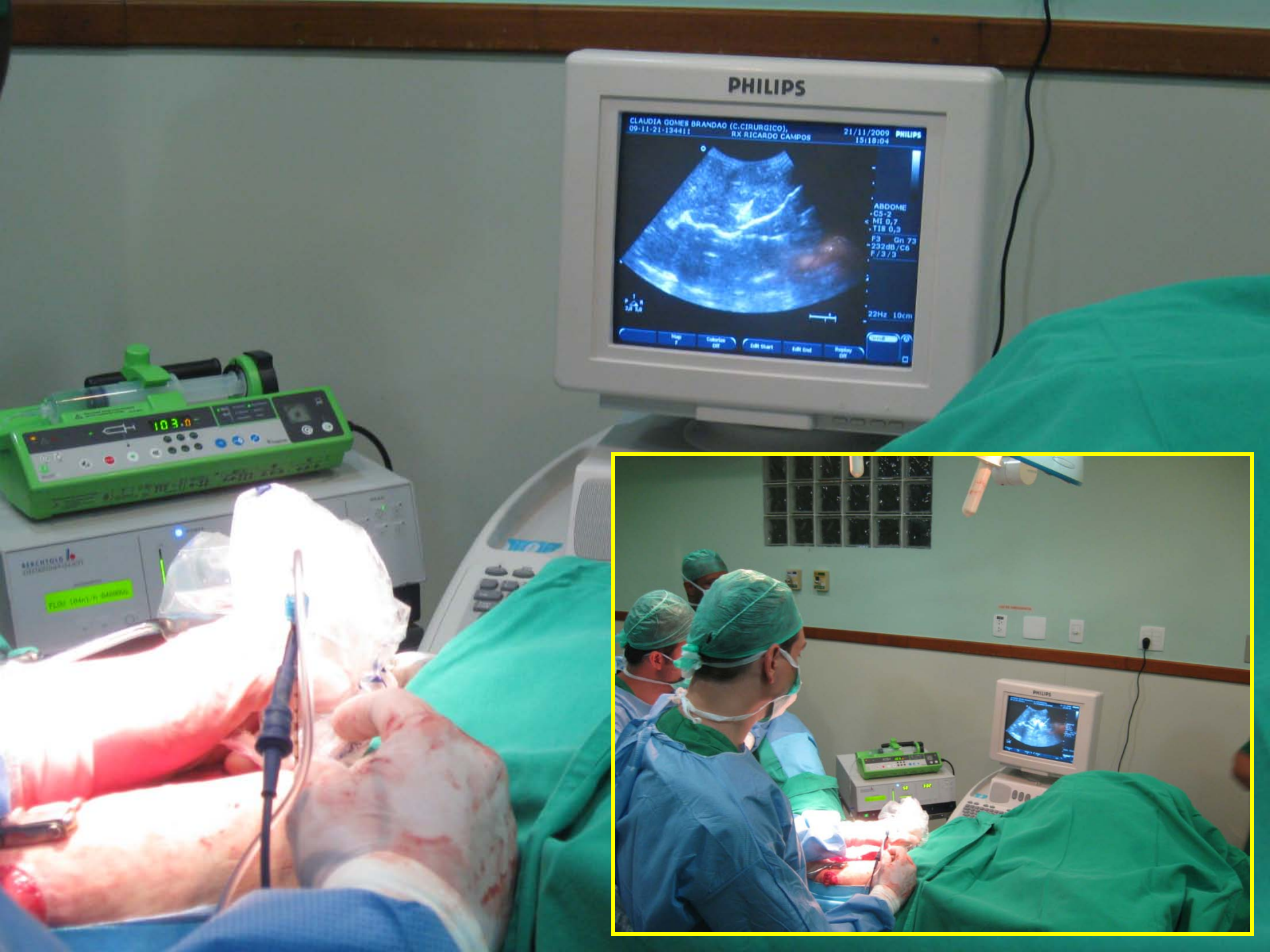

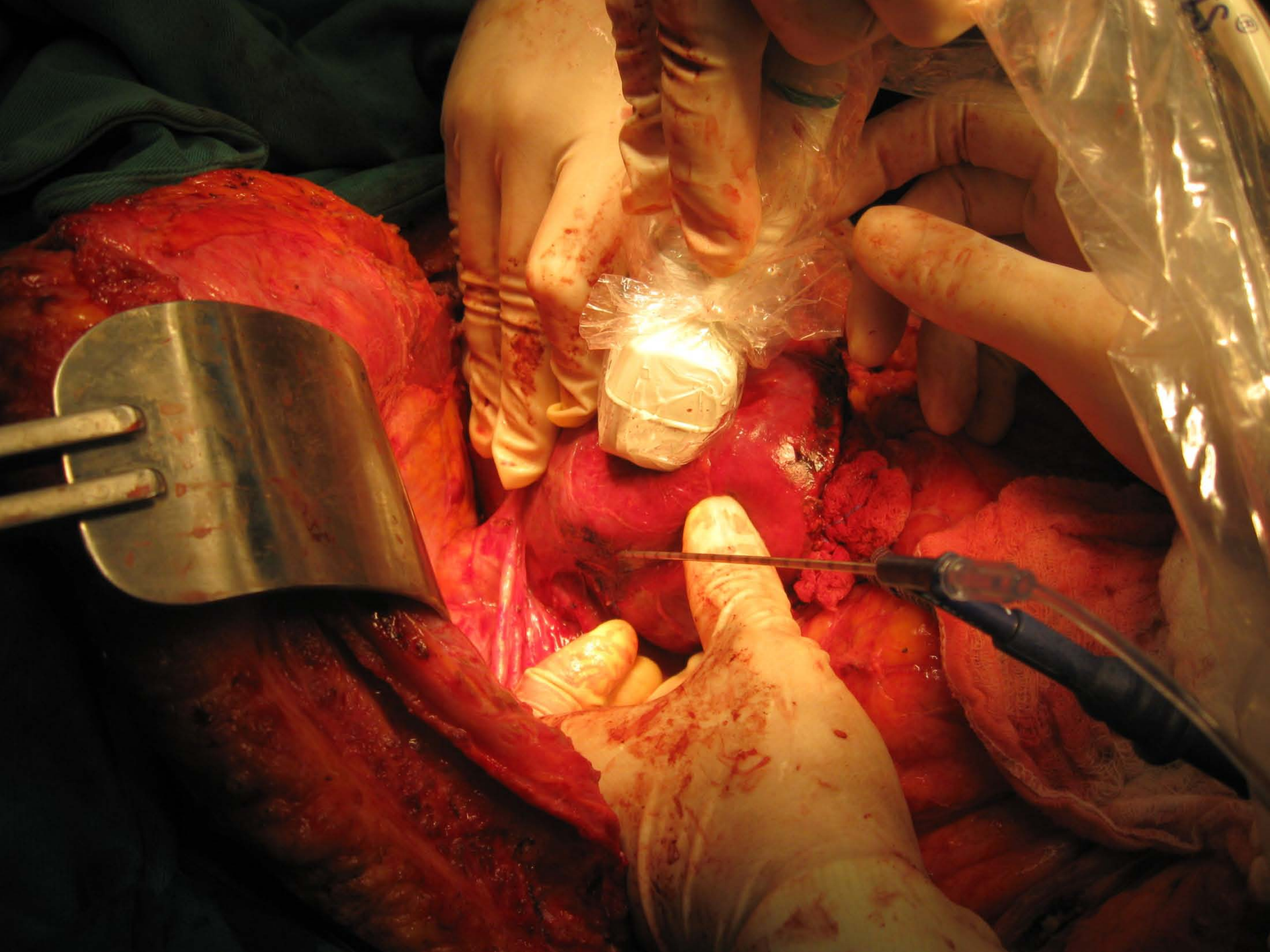




RADIOABLAÇÃO

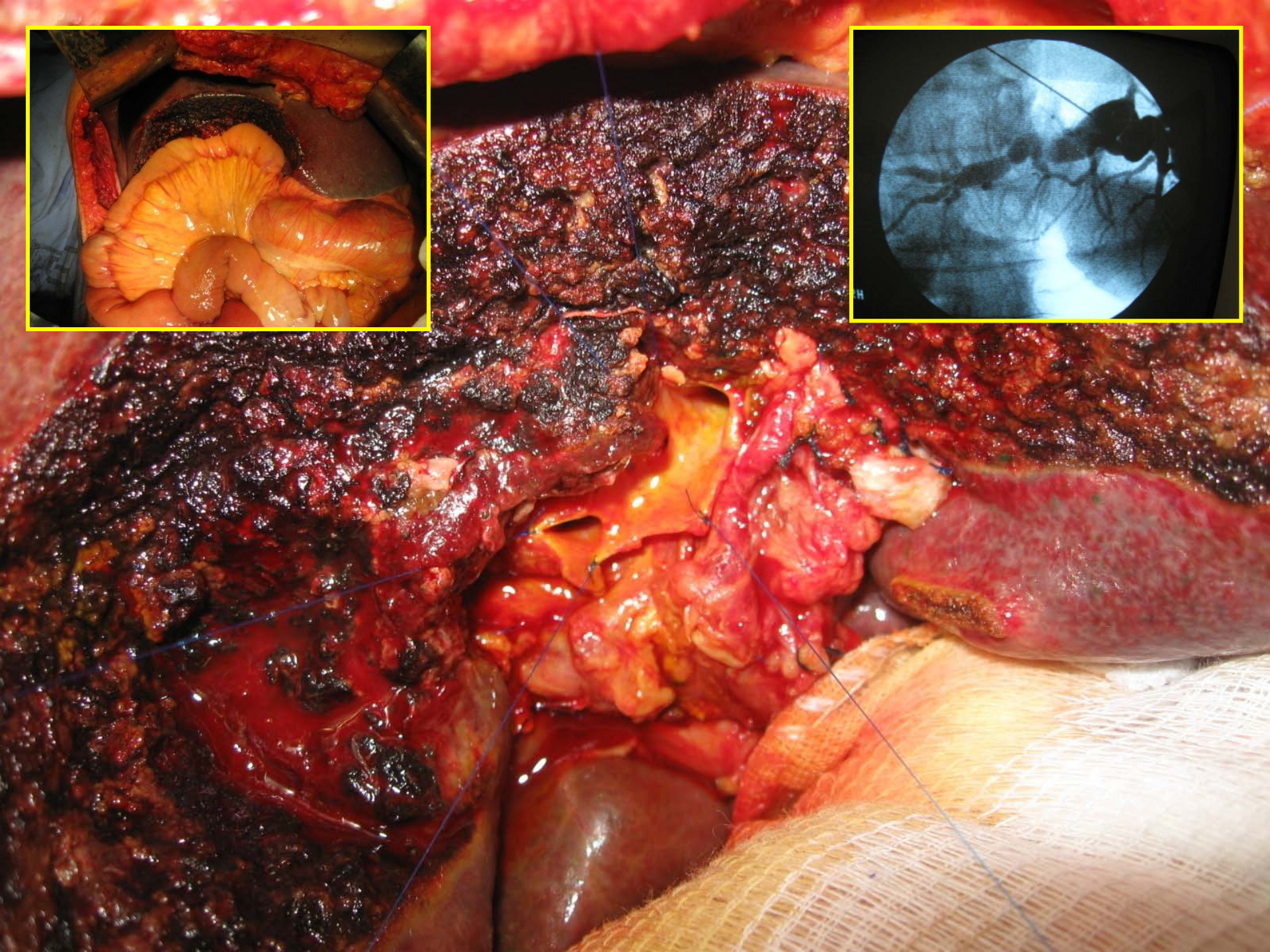
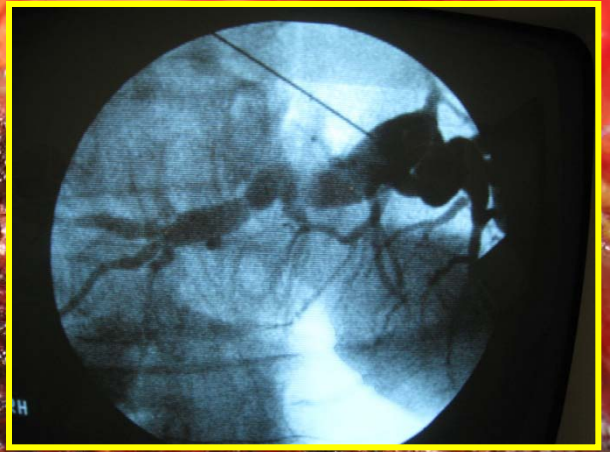
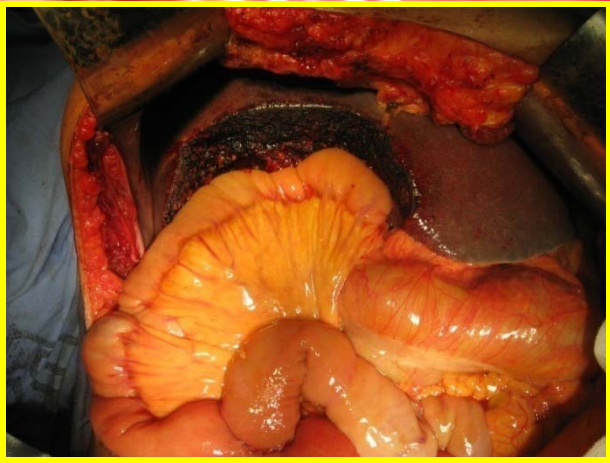per-operatória / guiada por USG





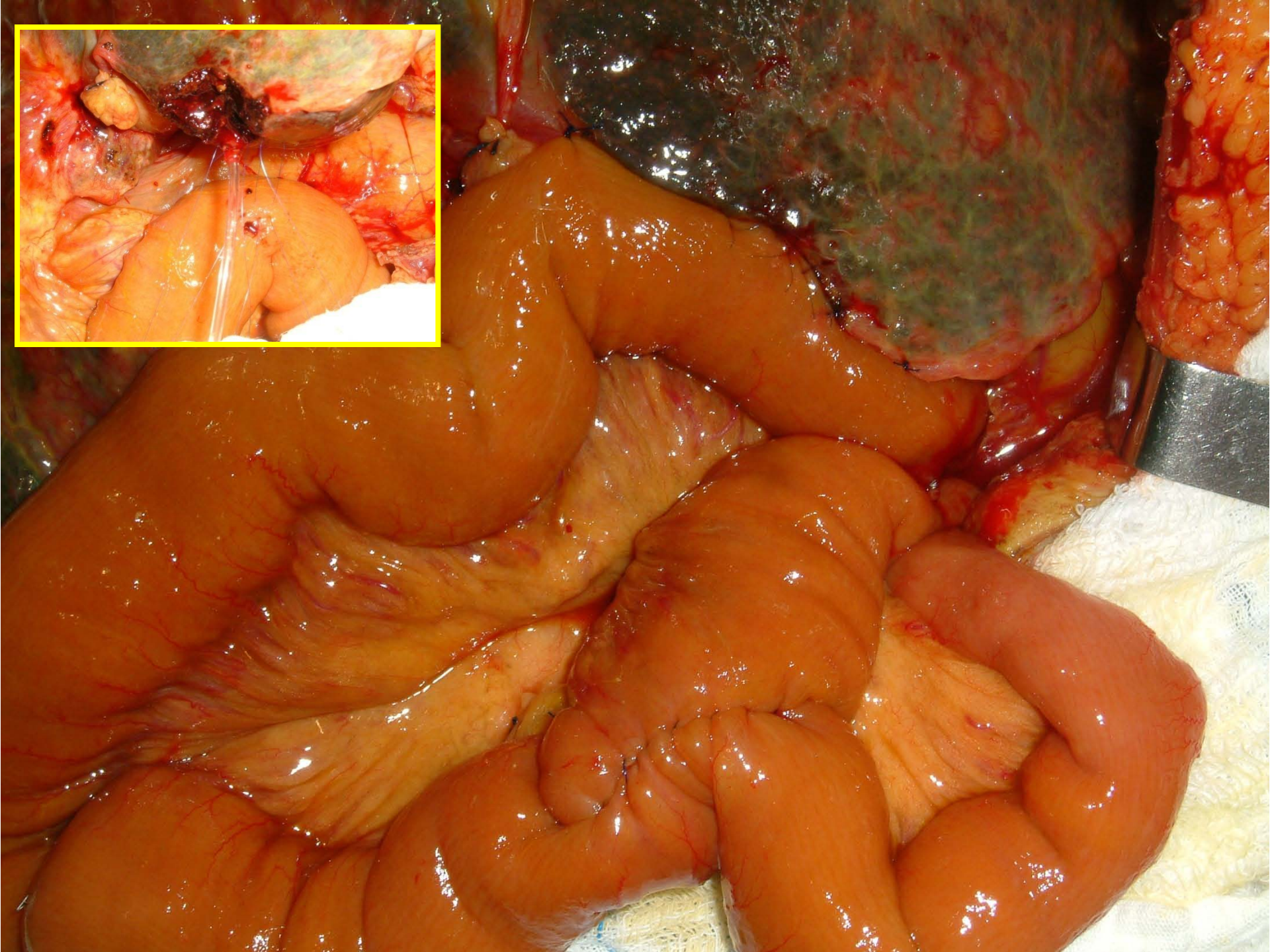
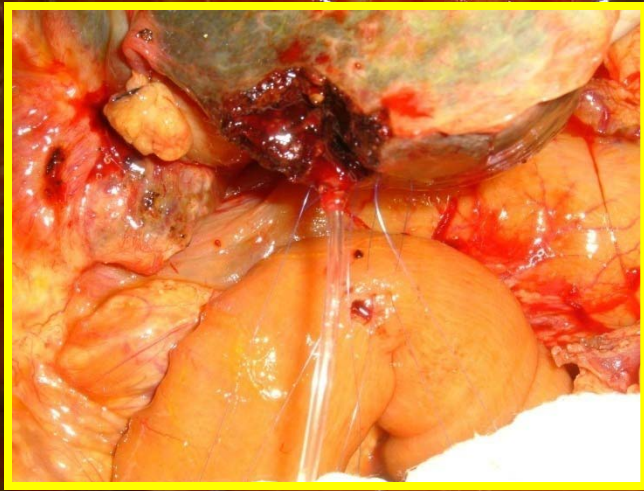
RESSECÇÃO DA VIA BILIAR PRINCIPAL +
SEGMENTECTOMIA IVb
“Cirurgia de Bismuth”

COLANGIARCINOMA

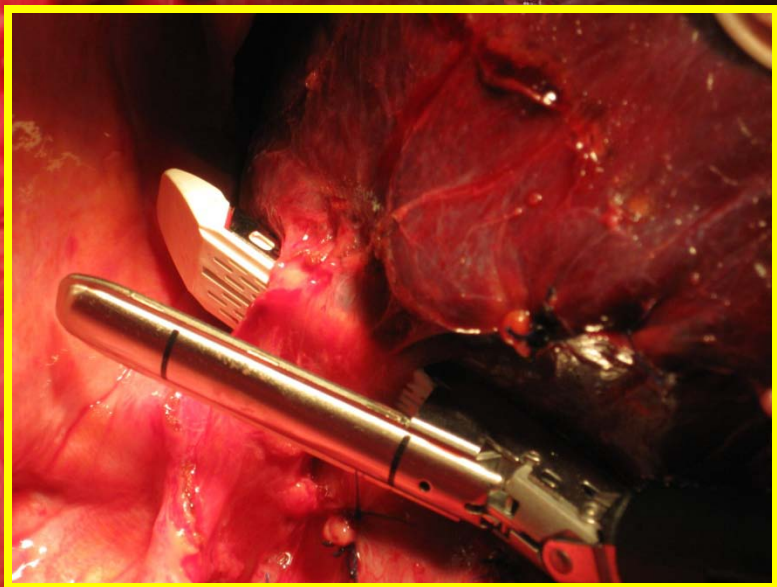
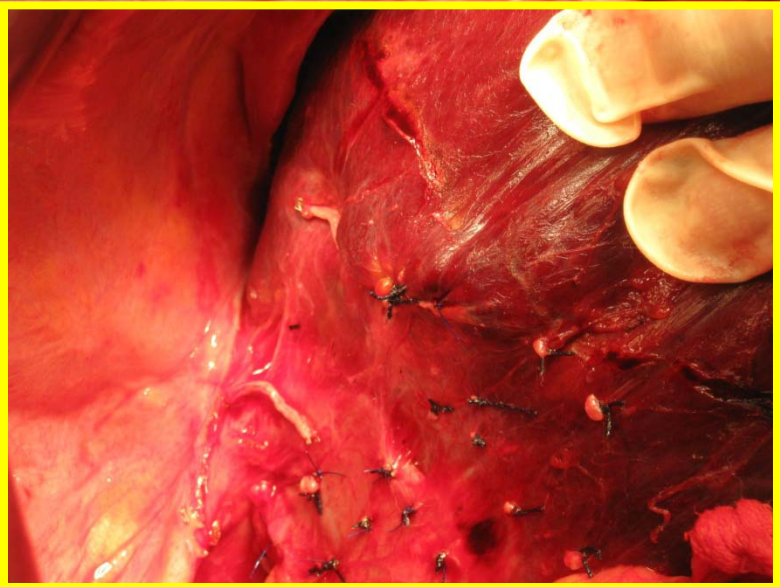
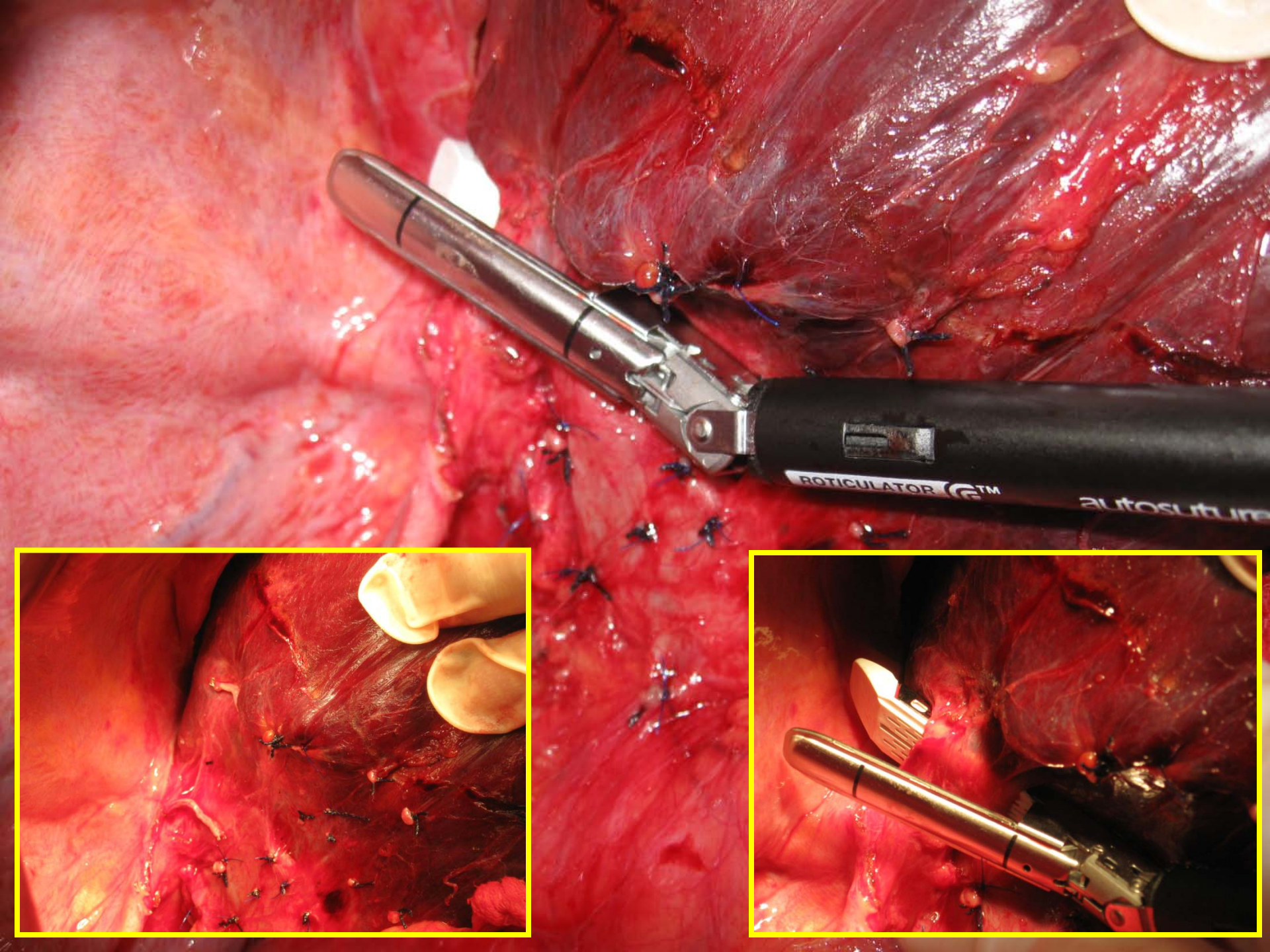


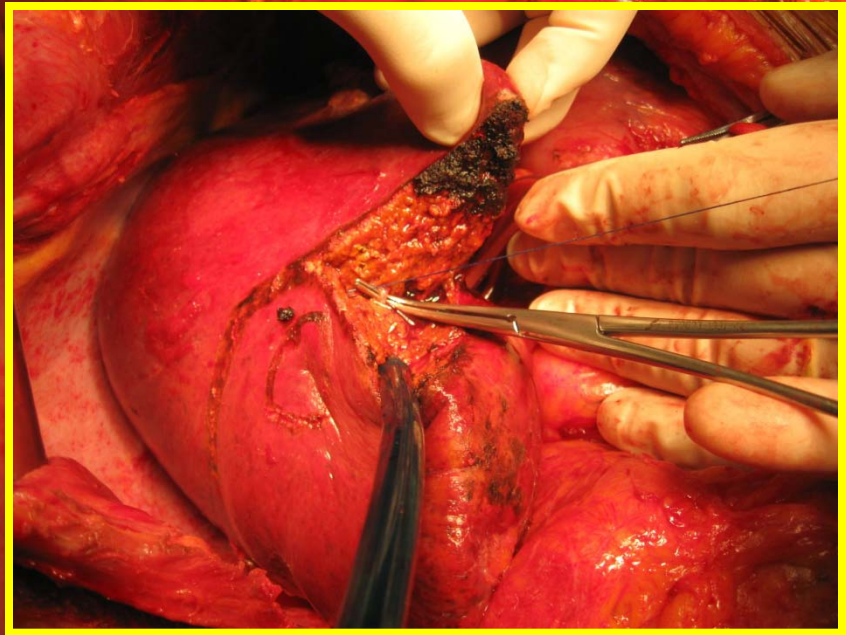
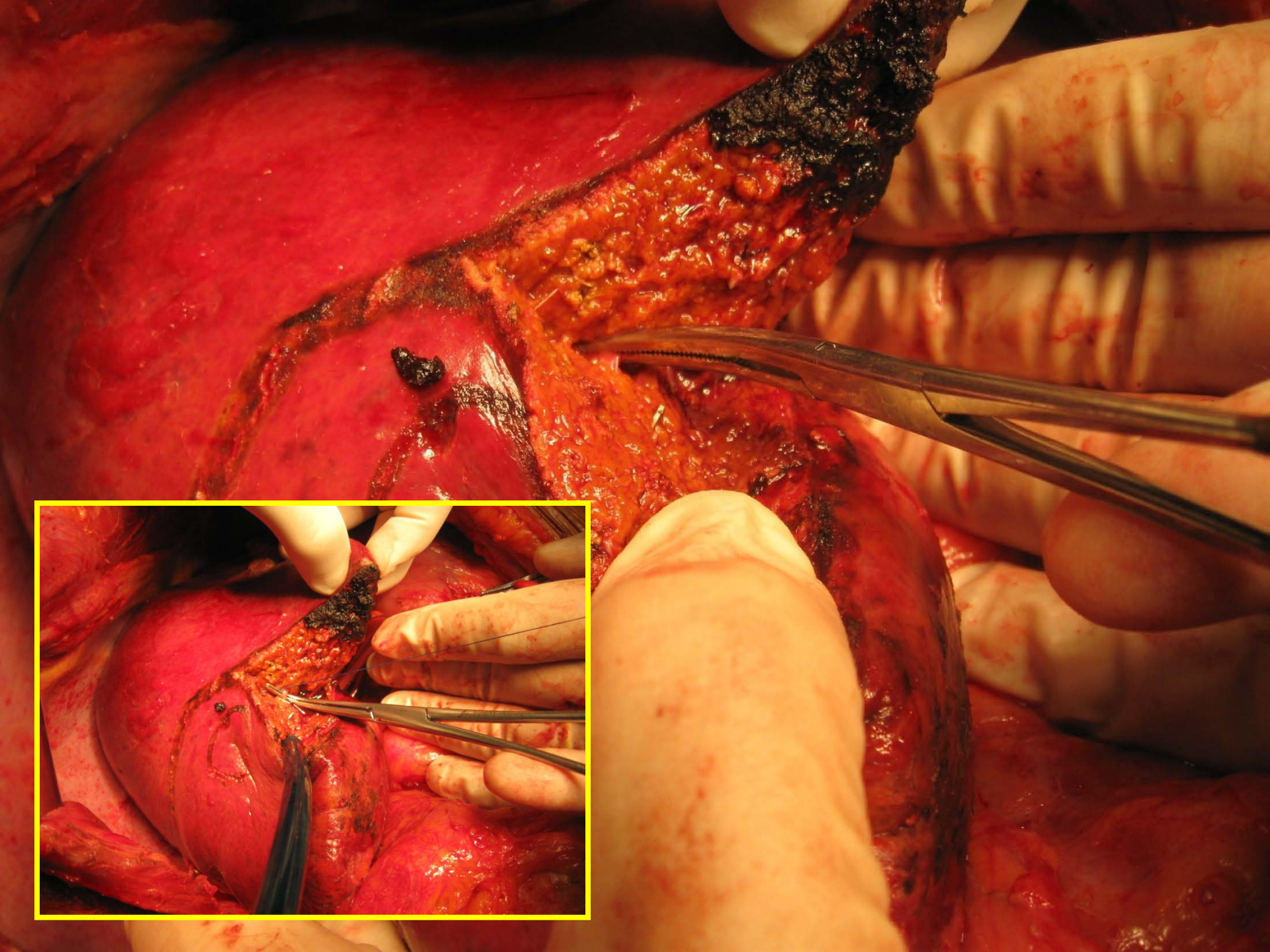
BILEODIGESTIVA INTRA-HEPÁTICA
“Couinaud-Soupault”

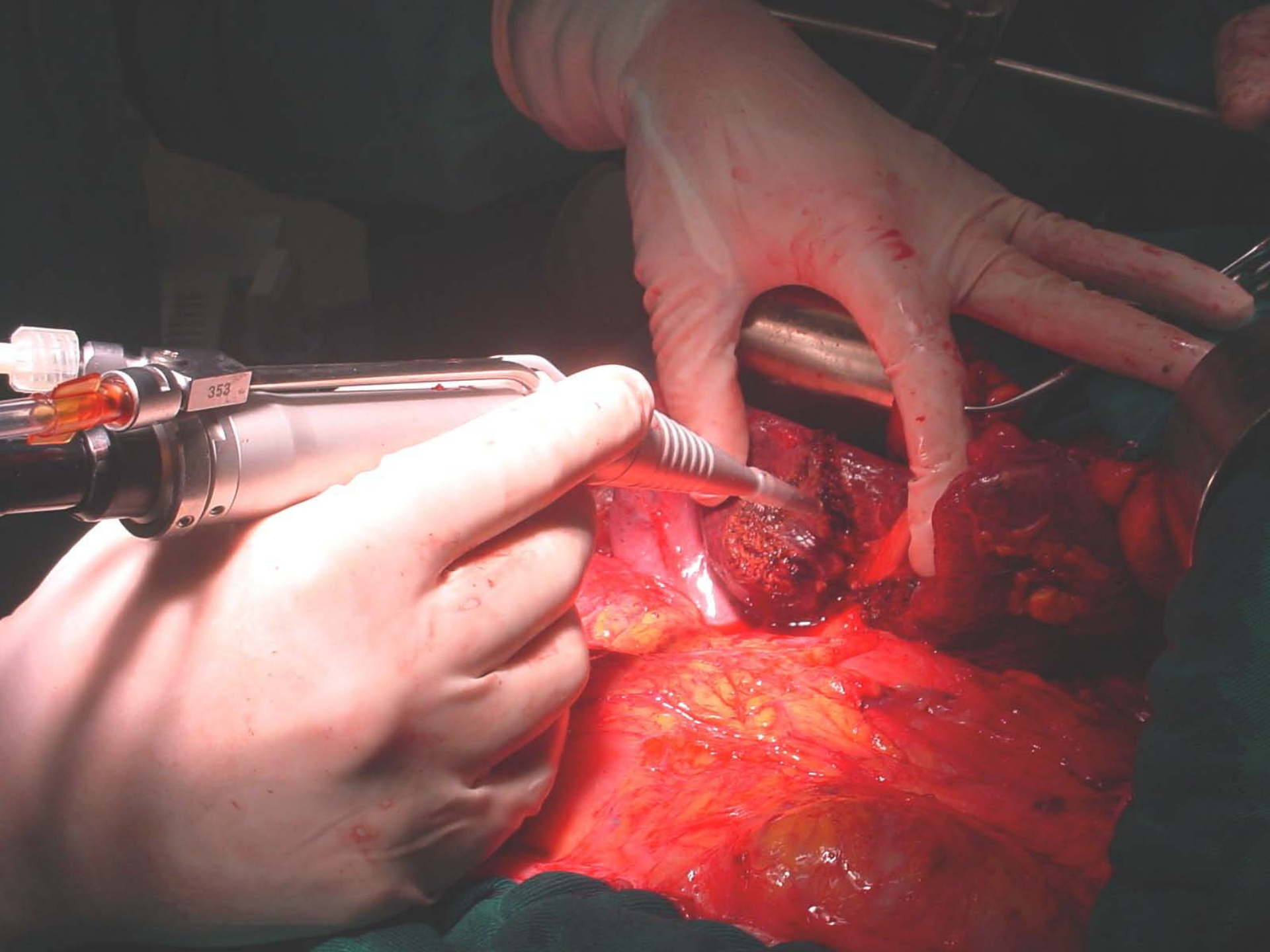
COLANGIARCINOMA

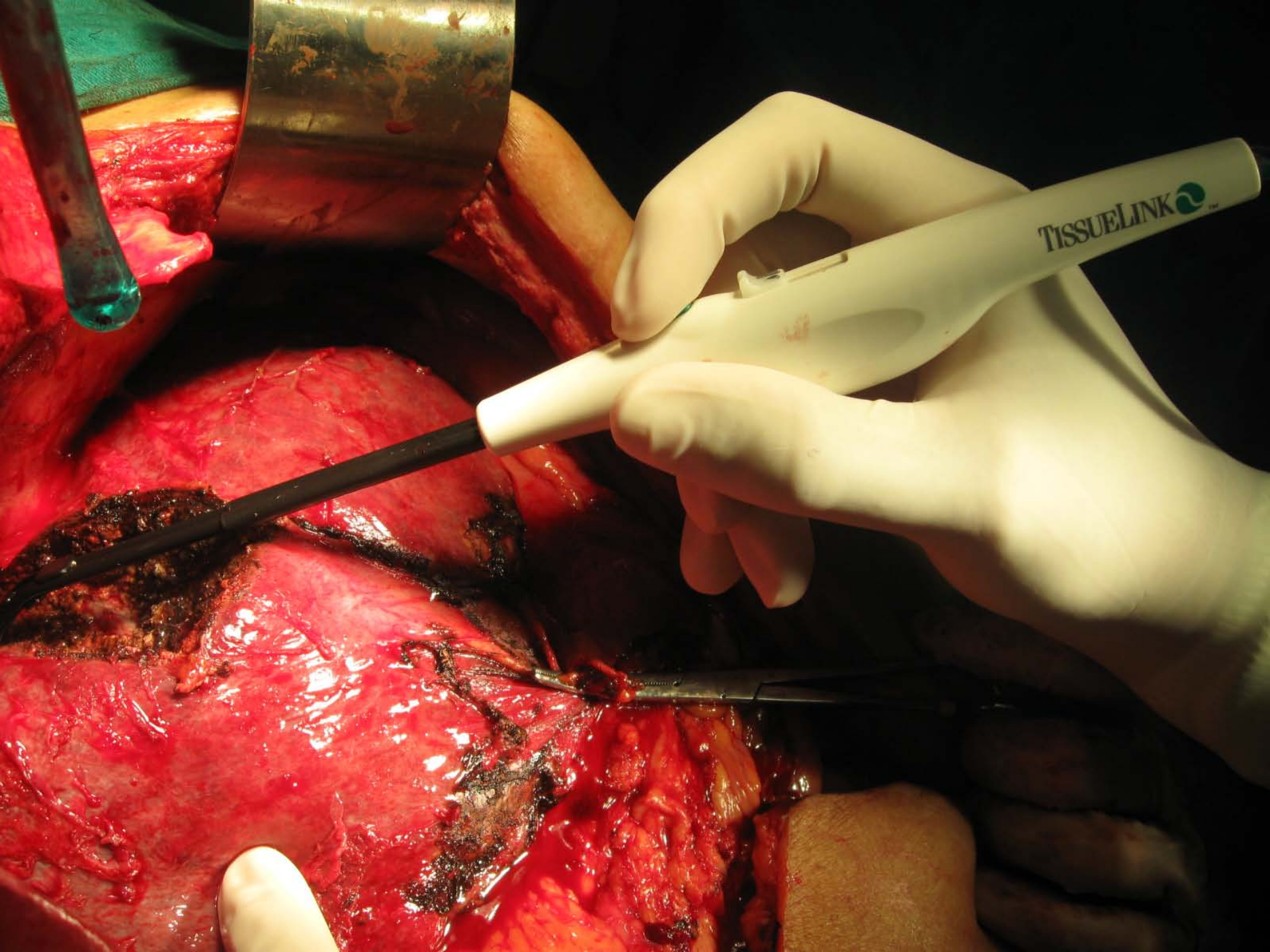


TÉCNICAS DE TRANSECÇÃO DO PARÊNQUIMA HEPÁTICO

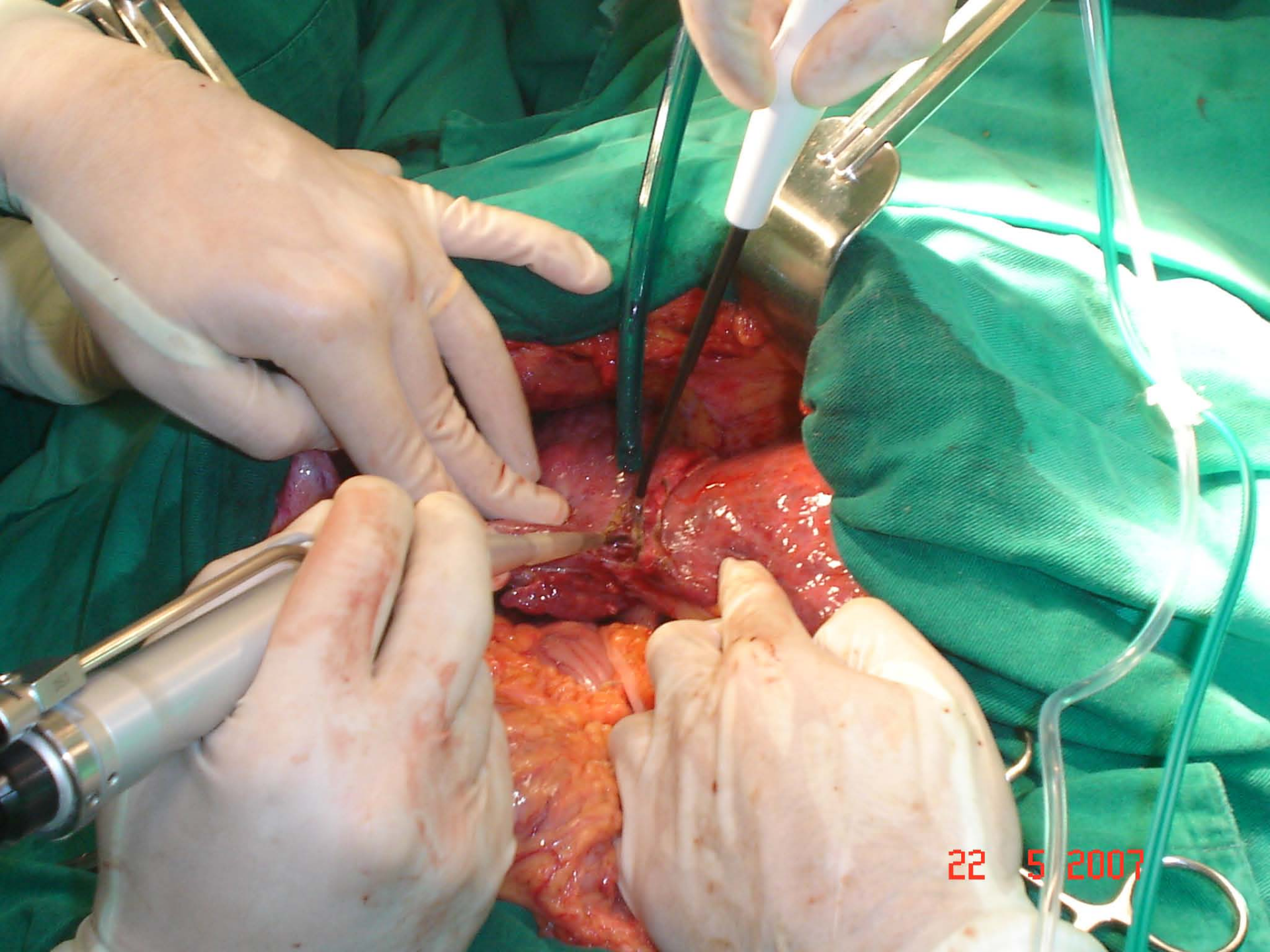






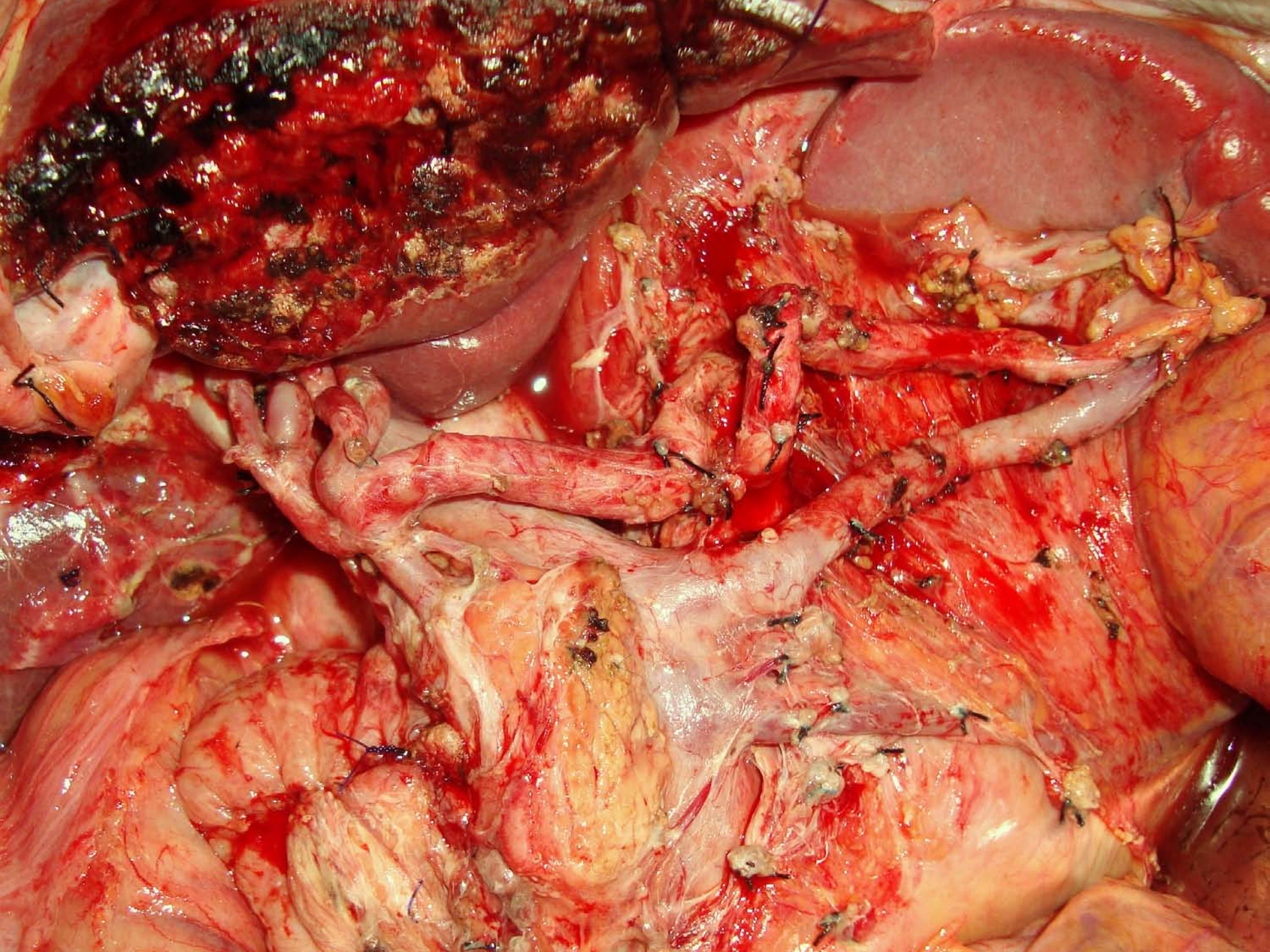


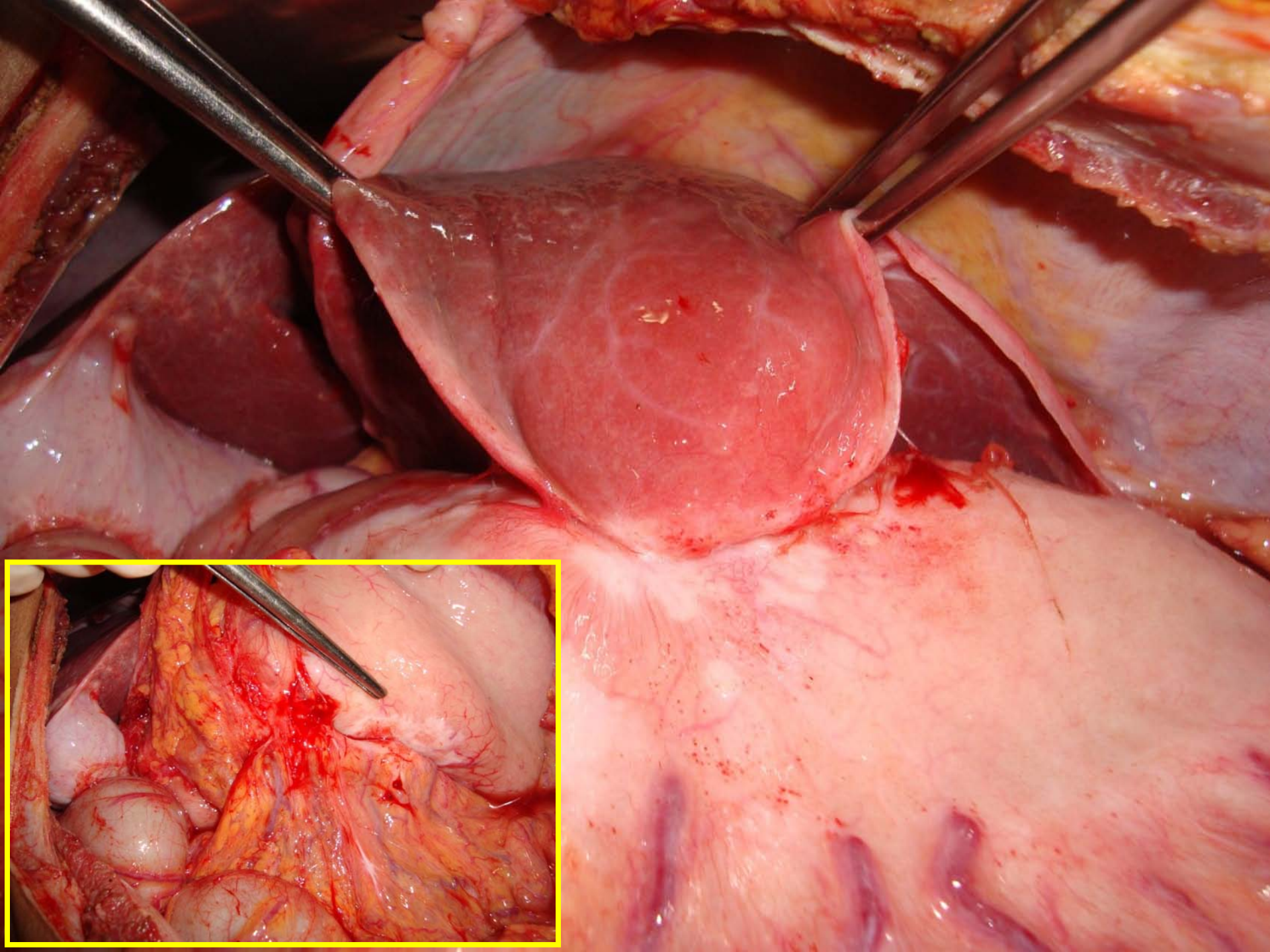
TISSUELINK

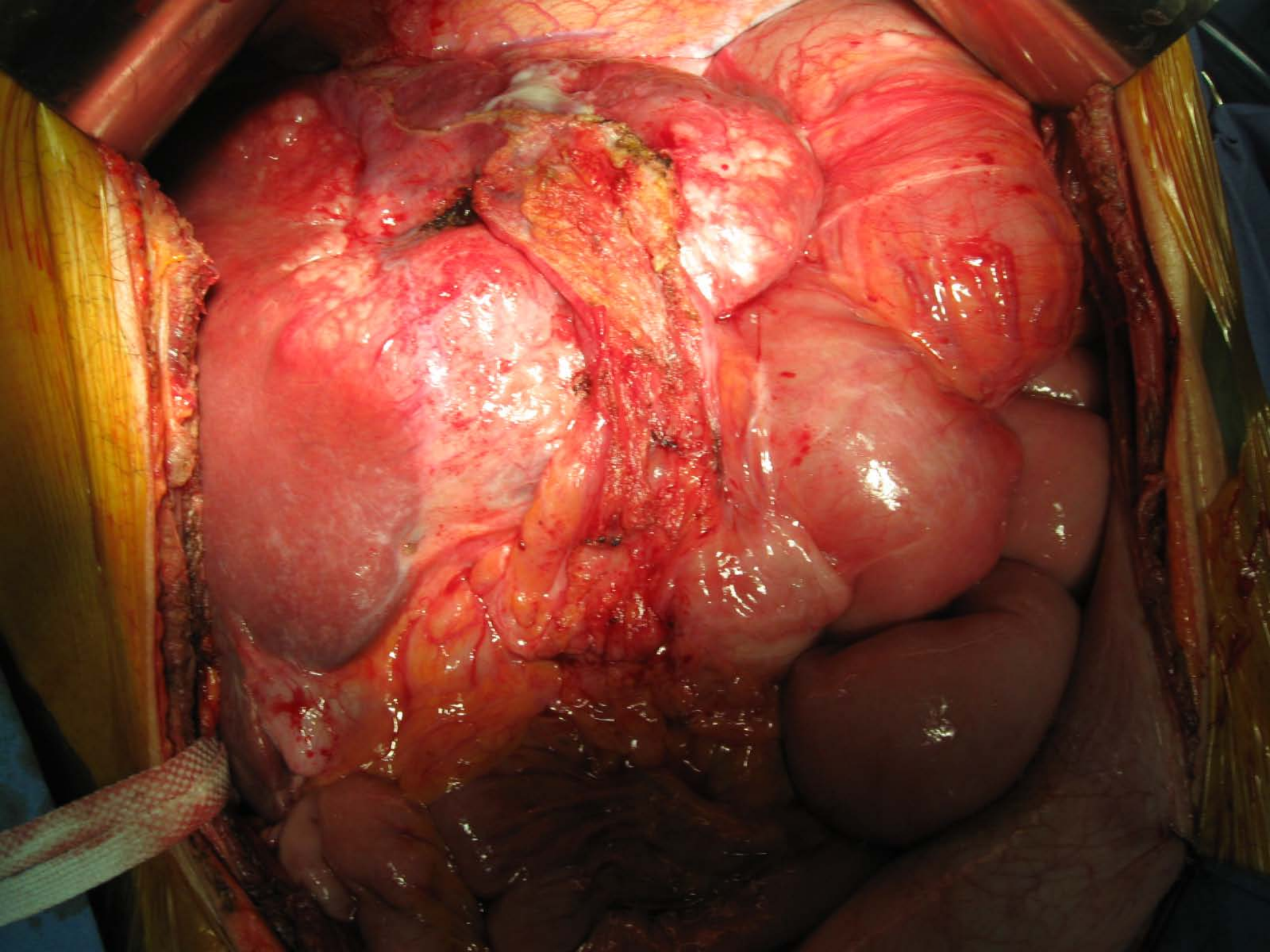


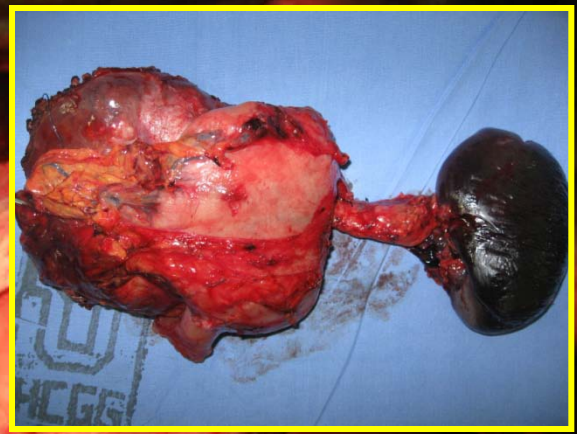
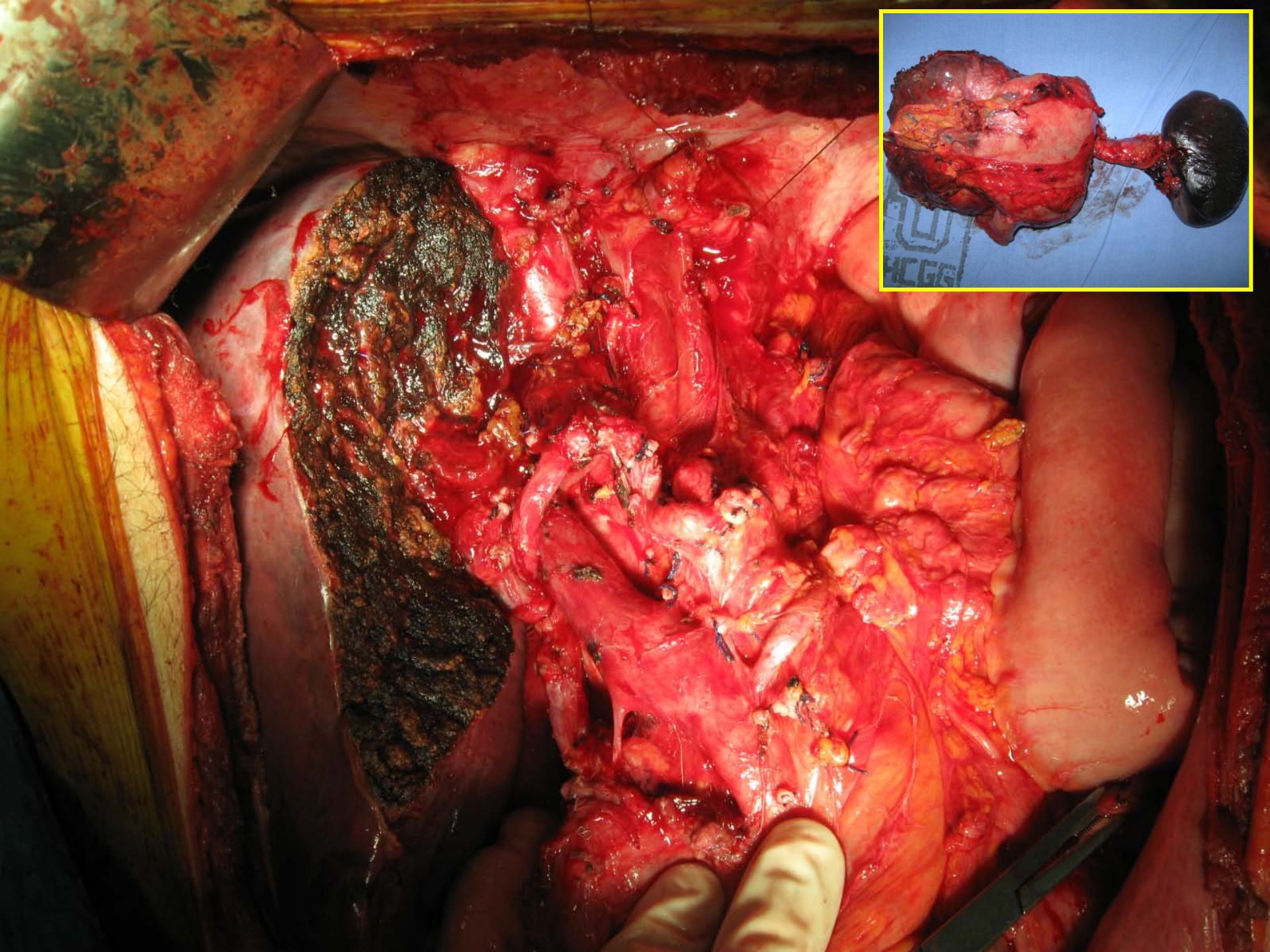
22 5 2007

CIRURGIAS MULTIVISCERAIS

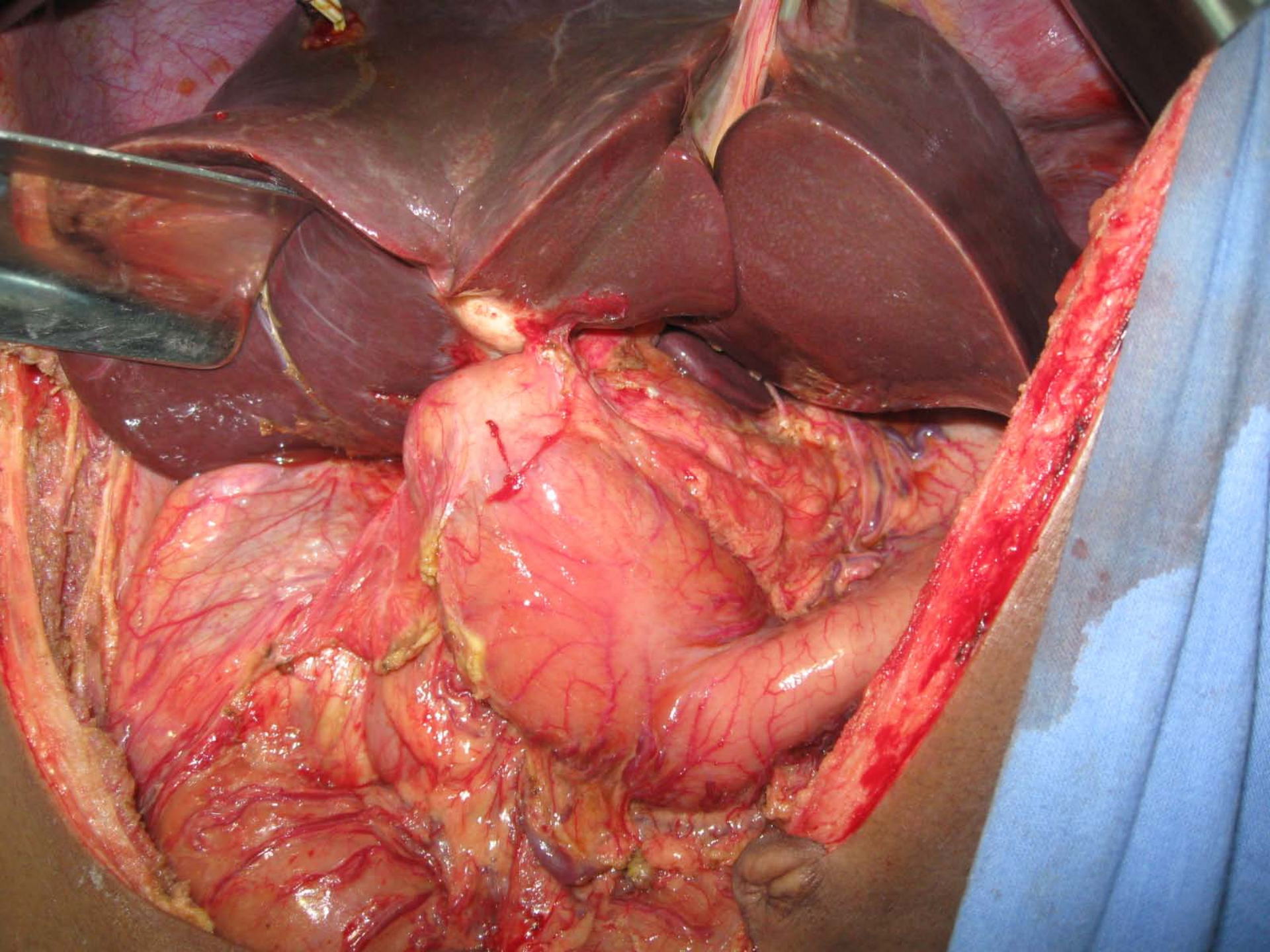


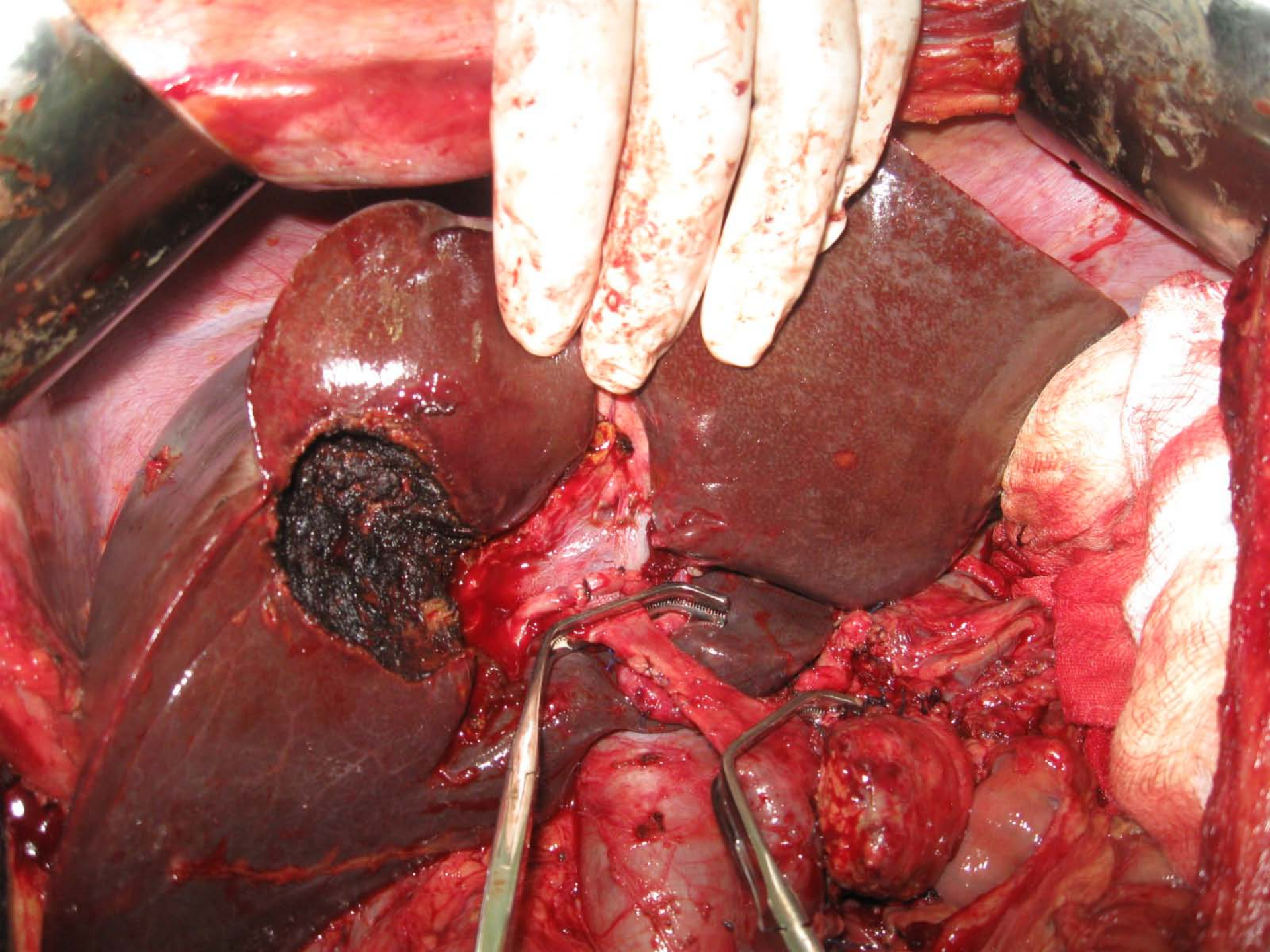


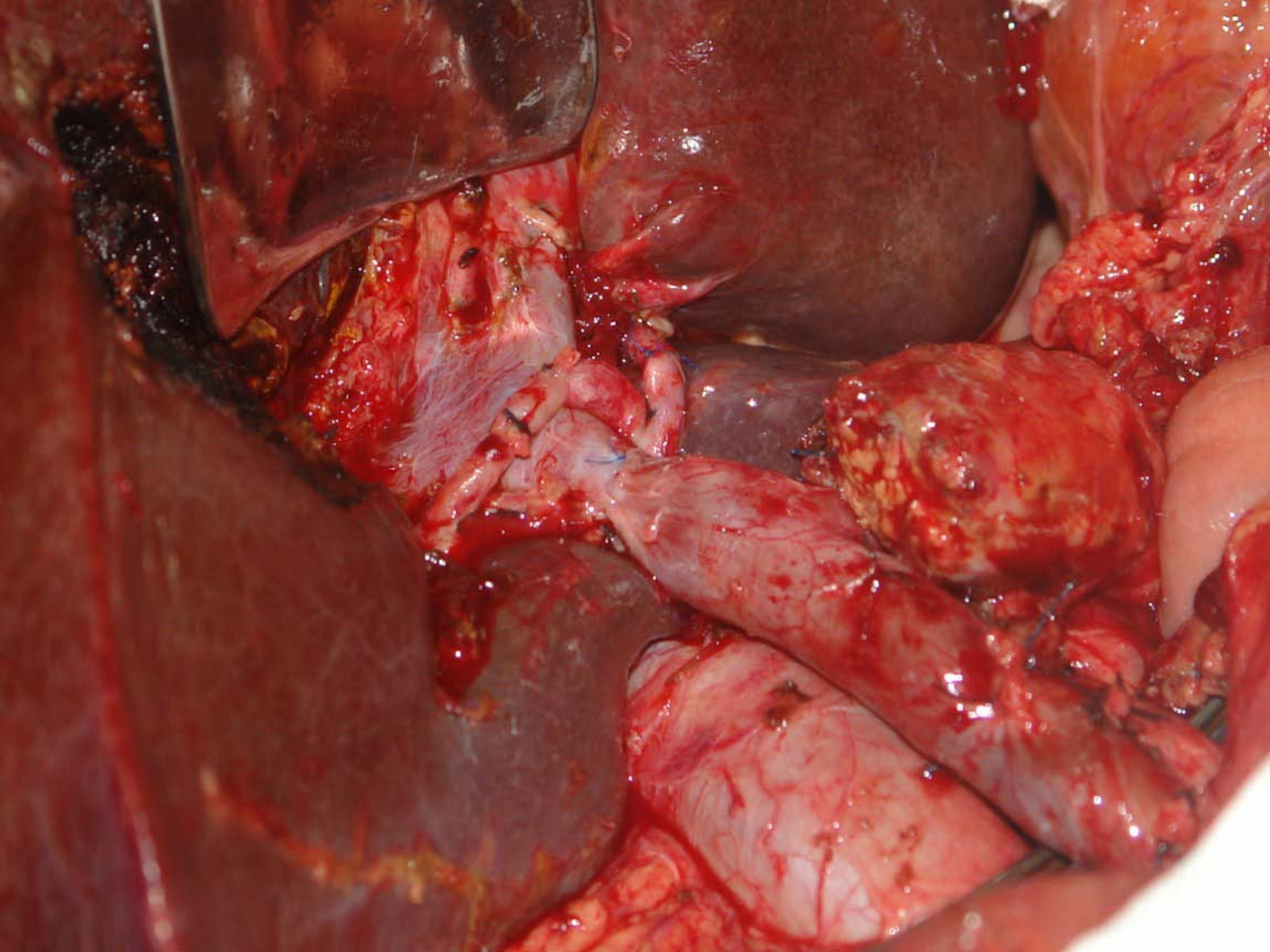




RESSECÇÕES VASCULARES ASSOCIADAS







RESSECÇÕES VASCULARES COM PRÓTESES

